



Digestive Sarcoidosis: About 11 Cases

Mzabi Anis, Thabet Maissa*, Zorgati Hend, Boufares Ahmed, Anoun Jihed, Ben Fredj Fatma, Rezgui Amel and Laouani Chedia

Department of Internal Medicine, Sahloul Hospital, Faculty of Medicine of Sousse, Tunisia

***Corresponding Author:** Thabet Maissa, Department of Internal Medicine, Sahloul Hospital, Faculty of Medicine of Sousse, Tunisia.

Received: September 26, 2020

Published: February 08, 2021

© All rights are reserved by **Thabet Maissa, et al.**

Abstract

During sarcoidosis, digestive involvement is rare and occurs mainly in a context of multisystemic condition. It can affect all segments of the digestive tract. We conducted 11 patients with digestive sarcoidosis (9 women and 2 men) of average age at diagnosis 44.16 years [26 - 75]. The revealing symptoms were mainly weight loss and abdominal pain in 8 cases respectively. Digestive involvement was isolated in 4 cases, revealing in 5 cases and associated with mediastino-pulmonary involvement (n = 2), ocular involvement (n = 2) and neurological involvement (n = 2). Hepatomegaly was found in 7 cases: splenomegaly in 4 cases. The multinodular aspect of hepatosplenomegaly was noted in 3 cases. Two patients had pancreatic involvement and one had gastric involvement. The angiotensin converting enzyme was measured in all of our patients and was increased in 7 patients with a mean of 98.72 IU/ml. The treatment included corticosteroid therapy in all cases; methotrexate in 1 case and 4 patients were on PPI.

Keywords: Digestive Tract Sarcoidosis; Sarcoidosis; Hepatomegaly; Splenomegaly

Introduction

Sarcoidosis is a chronic noncaseating granulomatosis, it is reported in 4.7 to 64/100000 habitants [1]. Lungs and chest lymph nodes are mainly affected, but other organs can be reach in 30% to 50% of cases [2]. Digestive tract involvement is extremely rare [3]. The whole digestive tract can be involved but only a few case reports have described mainly gastric involvement [4,5].

Objective of the Study

The objective of this study was to determine the radiological, clinical and evolution features of digestive involvement of sarcoidosis.

Materials and Methods

From a retrospective series of 42 patients hospitalized in the Sahloul internal medicine department for systemic sarcoidosis

over a period from 1999 to 2019, we conducted 11 patients with digestive sarcoidosis.

The diagnosis of sarcoidosis was based on clinical and radiological features associated with the presence of noncaseating granulomas in the absence of other granulomatous disorders and the presence of noncaseating granulomas in any digestive tract segment and digestive clinical symptoms.

Results

There were 9 women and 2 men of average age at diagnosis 44.16 years [26 - 75]. The revealing symptoms were mainly weight loss and abdominal pain in 8 cases respectively. Hepatic cytolysis and cholestasis were noted in 5 cases each.

Digestive involvement was isolated in 4 cases, revealing in 5 cases and associated with mediastino-pulmonary involvement (n

= 2), ocular involvement (n = 2) and neurological involvement (n = 2). Digestive involvement was initiated by pancytopenia in 2 cases.

Hepatomegaly was found in 7 cases; splenomegaly in 4 cases. The multinodular aspect of hepatosplenomegaly was noted in 3 cases (Figure 1 and 2). Two patients had pancreatic involvement and one had gastric involvement. The diagnosis of sarcoidosis was confirmed histologically by a liver biopsy (n = 7), a lymph node biopsy under mediastinoscopy (n = 1), a bone biopsy (n = 1) and a bronchial biopsy (n = 1). A biological inflammatory syndrome was observed in 5 patients and hypergammaglobulinemia in 2 patients. The angiotensin converting enzyme was measured in all of our patients and was increased in 7 patients with a mean of 98.72 IU/ml. The treatment included corticosteroid therapy in all cases; methotrexate in 1 case and 4 patients were on PPI.

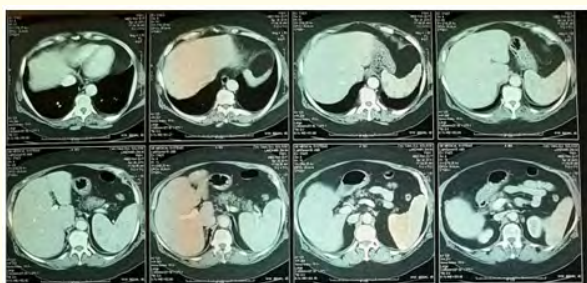


Figure 1: Abdominal CT scan showing multinodular splenomegaly.

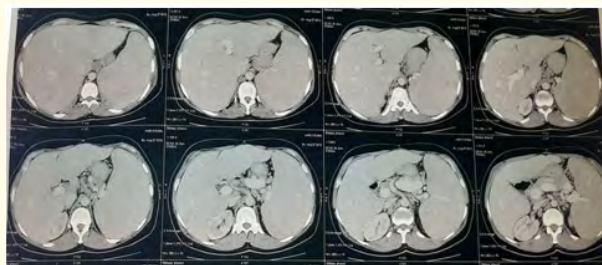


Figure 2: Abdominal CT scan showing multinodular hepatosplenomegaly.

Discussion

Sarcoidosis is a rare non-caseating granulomatosis disease that can affect mainly pulmonary and lymphatic tract but other organs

can be concerned [5]. Digestive sarcoidosis is rarely reported, but it can be underestimated because of asymptomatic form or nonspecific symptoms mainly a weight loss and digestive symptoms (abdominal pain, nausea, vomiting...) [3]. Sarcoidosis may affect every segment of the digestive tract, but the gastric is the most frequent site [3]. Usually, digestive sarcoidosis is associated with multivisceral granulomatous involvement. In our patients only one patient had stomach involvement and the frequent disease location was Hepatomegaly.

Histology confirmed the diagnosis of sarcoidosis in all cases showing a noncaseating granulomas in the biopsy specimens. The angiotensin-converting enzyme is increased in 7 patients. It is an important element to help physicians to make the diagnosis of sarcoidosis, which is in line with other studies showing that it is elevated in 60 - 75% of the patients with untreated sarcoidosis [6].

In agreement with our findings, hepatosplenomegaly was the most radiological findings which are consistent with other studies [7,8]. Abdominal CT scan showed a multinodular aspect of hepatosplenomegaly in only 3 patients.

Considering the treatment of digestive tract involvement, we could not precisely evaluate the efficiency of treatment on it because the treatment was sometimes initiated for other organ involvement [3].

Evidence-based guidelines for the treatment of sarcoidosis of the liver are also lacking. Patients usually receive no treatment or are treated pragmatically with corticosteroids. Some studies demonstrated the value of tumor necrosis factor (TNF)- α antagonists in pulmonary and neurological involvements [9]. TNF- α antagonists could be interesting to consider for digestive tract involvement.

Conclusion

Digestive sarcoidosis is rare form that can affect all segments of the digestive tract. It occurs mainly in a context of multisystemic condition. The angiotensin-converting enzyme, histology and radiology features may help to make the diagnosis of digestive sarcoidosis.

Bibliography

1. Valeyre D., et al. "Sarcoidosis". *Lancet* 383 (2014): 1155-1167.
2. Baughman RP., et al. "Clinical characteristics of patients in a case control study of sarcoidosis". *American Journal of Respiratory and Critical Care Medicine* 164 (2001): 1885-1889.

3. Ghrenassia E., *et al.* "Digestive-tract sarcoidosis: French nationwide case-control study of 25 cases". *Medicine* 95.29 (2016): e4279.
4. Ebert EC., *et al.* "Gastrointestinal and hepatic manifestations of sarcoidosis". *The American Journal of Gastroenterology* 103 (2008): 3184-3192.
5. Vahid B., *et al.* "Sarcoidosis of gastrointestinal tract: a rare disease". *Digestive Diseases and Sciences* 52 (2007): 3316-3320.
6. Mota C., *et al.* "Multisystemic Sarcoidosis with Early Gastrointestinal Symptoms". *Portuguese Journal of Gastroenterology* 24.3 (2017): 137-141.
7. Warshauer DM., *et al.* "Nodular sarcoidosis of the liver and spleen: analysis of 32 cases". *Radiology* 195.3 (1995): 757-762.
8. Gezer NS., *et al.* "Abdominal sarcoidosis: cross-sectional imaging findings". *Diagnostic and Interventional Radiology* 21.2 (2015): 111-117.
9. Judson MA., *et al.* "Efficacy of infliximab in extrapulmonary sarcoidosis: results from a randomised trial". *European Respiratory Journal* 31 (2008): 1189-1196.

Assets from publication with us

- Prompt Acknowledgement after receiving the article
- Thorough Double blinded peer review
- Rapid Publication
- Issue of Publication Certificate
- High visibility of your Published work

Website: www.actascientific.com/

Submit Article: www.actascientific.com/submission.php

Email us: editor@actascientific.com

Contact us: +91 9182824667