



## Multiple Repeated Coronary Bypass Surgery Using the MICS Method with Using an Intraoperative Flowmeter

**Kazaryan AV\*, Sigaev IY, Starostin MV, Keren MA, Morchadze BD, Pilipenko IV, Kydachev IF and Shoniya ZD**

*A.N. Bakulev National Medical Research Center of Cardiovascular Surgery, Moscow, Russian Federation, Russia*

**\*Corresponding Author:** Kazaryan AV, A.N. Bakulev National Medical Research Center of Cardiovascular Surgery, Moscow, Russian Federation, Russia.

**Received:** December 08, 2020

**Published:** January 11, 2021

© All rights are reserved by **Kazaryan AV., et al.**

### Abstract

Repeated coronary bypass surgery (redo-CABG) is still an operation of increased complexity and accompanied by a higher risk of morbidity and mortality compared to the primary CABG. Resternotomy remains the most necessary access in surgical practice with repeated heart surgery, despite a recognized high risk. The high risk of redo-CABG is largely due to technical difficulties: re-access and cardiolysis. The shortcomings of resternotomy have led to the development of alternative access to the heart, including for the implementation of redo-CABG. The purpose of our communication is to provide a clinical case of successful redo-CABG using the MICS technique. Output. Performing redo-CABG on the method of MICS in patients with the return of angina after CABG leads to an improvement in the results of surgical treatment: reducing the frequency of complications associated with resternotomy and shortening the rehabilitation period.

**Keywords:** Repeat Coronary Bypass Surgery; Thoracotomy; Transit Time Flow Measurement; MICS CABG

### Introduction

Due to the increase in the number of primary heart surgery, the number of patients requiring repeated surgical treatment is constantly increasing worldwide. Regardless of experience, all surgical schools recognize the increased risk of repeated coronary bypass surgery, explaining this not only by the repeated nature of the intervention, also by specific features that increase the likelihood of perioperative complications.

Resternotomy remains the most necessary access in surgical practice with repeated heart surgery, despite a recognized high risk of injury to functioning shunts and heart structures. Numerous researchers emphasize that safe resternotomy is one of the main stages of re-surgery [1-6]. More recently, Roselli E.E. [7] stressed

that injuries occur regularly and today during repeated surgery, despite the efforts of the surgical team, this indicates that resternotomy can be successfully managed in controlled conditions, but in general practice, still creates significant risks. According to Subramanian V.A., if it is not possible to perform a safe resternotomy and a high risk of damage to functioning shunts, alternative surgical accesses should be considered [1]. These features during the resternotomy led to the development of alternative access to the heart, including for the implementation of the CABG: left-sided thoracotomy, right-sided thoracotomy, subxyphoid access, parasternal access, various variants of the lower partial sternotomy [8,9]. Numerous papers have presented the fundamental possibility of bypassing all veneer arteries in repeat patients through alternative access [9-14].

The purpose of our communication is to provide a clinical case of successful re-coronary bypass surgery of LAD and OM using the MICS (Minimally Invasive Coronary Surgery) method and intraoperative flowmeter. MICS operations are now widely used in our clinical practice to treat patients with recurring myocardial ischemia after CABG. This large group of diverse multiple CABG operations performed through mini-access (not sternotomy), regardless of the use of extra corporal circulation.

### Case Study

Patient S., 60 years, diagnosis: CHD. Post infarct cardiosclerosis (2007, 2019). Recurrent angina. Condition after LIMA-LAD, SVG – OM and PDA (2010 year). PCI RCA October 2019. EuroSCORE risk assessment: 6,2.

TTE: left atrium: 40 x 56 mm. Left ventricle: EDV 160.0 ml, EF 48 %, hypokinesia of the posterior-lateral segments.

Coronary angiograms - the left main coronary arteries stenosis 65%, LAD estuary up to 60%, in m/3 90-95%, in d/3 75%. OM in p/3 75%, in m/3 65%-95%. PL in/3 70-7%, occlusion in m/3. RCA in m/3 90%, in d/3 50%. PDA in p/3 85%, m/3 occlusion. Dysfunction of all shunts. After analyzing the coronary angiograms and the data of the multispiral CT, a systematic plan of the operation was developed.

### Surgical technique

After the introduction of the patient in anesthesia performed intubation of the trachea, using for this purpose intubation tubes for separate ventilation of the lungs. The position of the patient on the operating table: on the back with a roller placed at the level of the corner of the shoulder blade. Catheterization of femoral artery and vein has been performed to connect the conductor’s cardiopulmonary bypass if necessary. The skin incision of 11-12cm was performed in the V intercostal space. After performing thoracotomy in the inter-rib gap started a retractor, which bred ribs. The pericardium leaves and partial cardiolysis were dissected. At the same time as the thoracotomy was carried out fence great saphenous vein. A proximal anastomosis is superimposed on the pressed aorta with a rising aorta 6/0. Then a composite anastomosis is formed between venous grafts. Stabilization of the myocardium with the OCTOPUS system. Exposure to LAD in m/3. The artery with a diameter of 2 mm. In the formation of distal anastomosis, we used intracoronary shunts. The distal anastomosis is outage with LAD 7/0. Restored blood flow on LAD. The OM exhibition in m/3. Artery with a diameter of 2mm. Superimposed distal anastomosis is formed with OM thread is 7/0. Intraoperative transit time flow measurement (TTFM) has been performed. TTFM is a simple and effective way to assess blood flow by shunts during surgical myocardial revascularization. This method is not invasive, safe, easy to perform and reproduce, and provides real-time information on the hemodynamic properties of the shunt.

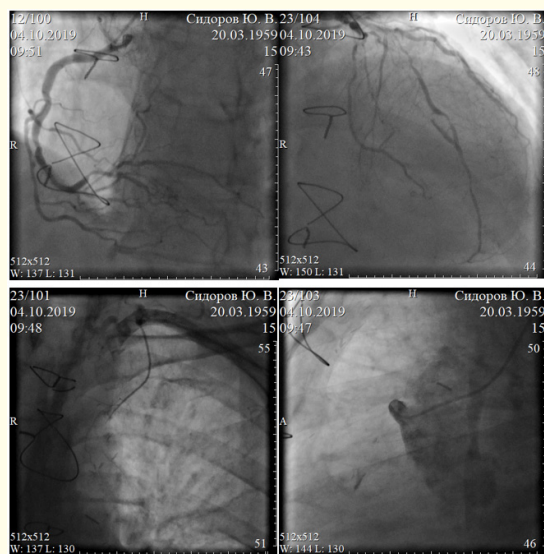


Figure 1: Coronary angiograms. Dysfunction of all grafts.

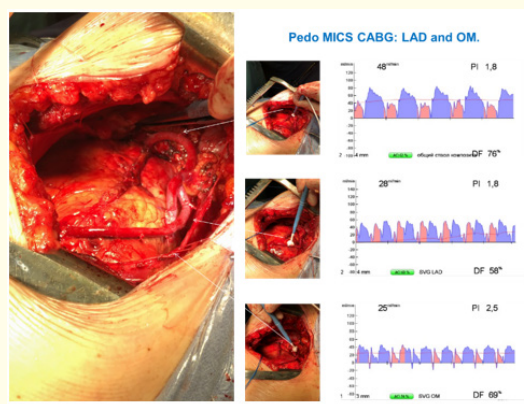


Figure 2: Left anterior thoracotomy: old (LIMA) and new grafts with using an intraoperative flowmeter.

Layering thoracotomy wound with drainage of the left pleural cavity. The operation lasted 198 minutes. The patient was extubated five hours after being removed from the operating room. The time spent in the intensive care unit was 16 hours. The early post-operative period proceeded smoothly. The patient was discharged in satisfactory condition on the 9<sup>th</sup> day after the operation.

## Conclusion

Many publications demonstrate a significant risk of injury during re-access to the heart. In view of the foregoing, the risk of re-sternotomy is often taken into account when choosing a global surgical strategy for a particular patient, and is considered one of the leading risk factors for the intervention itself, along with the patient's initial severe condition. The findings allow us to consider the MICS methodology as an alternative to the traditional CABG through sternotomy. We believe that the use of thoracotomy in repeated operations allows successful operations of myocardial revascularization, minimizing the risk of complications and leading to improved hospital results.

## Bibliography

- Subramanian VA. "Clinical experience with minimally invasive reoperative coronary bypass surgery". *European Journal of Cardio-Thoracic Surgery* 10 (1996): 1058-1062.
- Niinami H., et al. "Partial median sternotomy as a minimal access for off-pump coronary artery bypass grafting: Feasibility of the lower-end sternal split-ting approach". *Annals of Thoracic Surgery* 72 (2001): 1041-1045.
- Yaku H and Doi K. "Redo coronary artery bypass grafting". *General Thoracic and Cardiovascular Surgery* 62 (2014): 453-460.
- Ghanta R K., et al. "Evolving trends of re-operative coronary artery bypass grafting: An analysis of the Society of Thoracic Surgeons Adult Cardiac Surgery Database". 145 (2013): 364-372.
- Azoury FM., et al. "Off-pump reoperative coronary artery bypass grafting by thoracotomy: patient selection and operative technique". *Annals of Thoracic Surgery* 71 (2001): 1959-1963.
- Sabik JF., et al. "Occurrence and risk factors for reintervention after coronary artery bypass grafting". *Circulation* 114 (2006): 454-460.
- Roselli EE., et al. "Adverse events during reoperative cardiac surgery: frequency, characterization, and rescue". *Journal of Thoracic and Cardiovascular Surgery* 135 (2008): 316-323 (e1-6).
- Odeaa Al jabbari., et al. "Redo Coronary Artery Bypass Graft Surgery from the Descending Thoracic Aorta to the lateral wall of the Left Ventricle Via left Mini Thoracotomy". *2016 Annual Meeting Cardiac Track* (2016).
- Duvan I., et al. "Redo off-pump coronary artery bypass grafting via a left thoracotomy". *Cardiovascular Journal of Africa* 26.1 (2015): 25-28.
- De Bruyne B., et al. "Fractional flow reserve-guided PCI vs. medical therapy in stable coronary disease". *The New England Journal of Medicine* 367.11 (2012): 991-1001.
- D'Ancona G., et al. "Posterior thoracotomy for reoperative coronary artery bypass grafting without cardiopulmonary bypass: perioperative results". *Heart Surgery Forum* 3.1 (2000): 18-22; discussion 22-23.
- Sigaev IY., et al. "Repeated coronary artery bypass grafting PDA on a beating heart through right thoracotomy". *Grudnaya i serdechno-sosudistaya hirurgiya* 1 (2017): 56-59.
- Kazaryan A., et al. "Minimally invasive coronary surgery as a primary strategy for reoperative myocardial revascularization". The 26th Annual Meeting of the Asian Society for Cardiovascular and Thoracic Surgery (2018): 12.
- Sigaev IY., et al. "Repeated reconstruction of distal mammarocoronary anastomosis through left thoracotomy". *Patologiya krovoobrashcheniya i kardiokirurgiya* 19.4 (2019): 130-133.

### Assets from publication with us

- Prompt Acknowledgement after receiving the article
- Thorough Double blinded peer review
- Rapid Publication
- Issue of Publication Certificate
- High visibility of your Published work

Website: [www.actascientific.com/](http://www.actascientific.com/)

Submit Article: [www.actascientific.com/submission.php](http://www.actascientific.com/submission.php)

Email us: [editor@actascientific.com](mailto:editor@actascientific.com)

Contact us: +91 9182824667