



A Minimal Invasive Clitoral Hoodoplasty Technique with J-Plasma

Bülent Cihantimur*, **Özgür Ağlamış** and **Yavuz Özşular**

Department of Plastic Surgery, Estetik International Quasar Clinic, Turkey

*Corresponding Author: Bülent Cihantimur, Department of Plastic Surgery, Estetik International Quasar Clinic, Turkey.

DOI: 10.31080/ASMS.2020.05.0826

Received: November 27, 2020

Published: January 11, 2021

© All rights are reserved by **Bülent Cihantimur., et al.**

Abstract

Background: Various techniques have been identified for clitoral hoodoplasty that is commonly applied in cosmetic gynecology surgeries. The aim of this study is to investigate whether or not the technique applied with a minimally invasive and neuroprotective approach is effective in terms of cosmetic appearance and sexual function.

Material and Method: A total of 82 women were included in the study. During the operation, J-Plasma[®], using the plasma of helium gas as an energy source, was employed to dissect, coagulate, and tighten the clitoral hood and the surrounding tissue. All the participants were assessed with FGSIS and FSFI before the application and at 6th and 12th month after the application.

Results: No serious complication was observed in the long-term follow-up of the patients. While the FSFI mean score obtained by summing the scores of FSFI parameters was 24.1 ± 1.5 in the pre-treatment period, this value increased to 29.4 ± 1.5 and 30.4 ± 1.7 at the 6th and 12th months after the treatment, respectively. The difference between the pre-treatment, post-treatment 6th month, post-treatment 12th month FSFI mean scores was statistically significant. While the FGSIS mean score obtained by summing the scores of FGSIS parameters was 19.7 ± 1.8 in the pre-treatment period, this value increased to 21.9 ± 1.7 and 22.7 ± 1.8 at the 6th and 12th months after the treatment, respectively. The mean score in two periods after the treatment was also significantly higher than pre-treatment period.

Conclusion: This technique can be a new alternative minimal-invasive clitoral hoodoplasty technique by targeting minimal tissue extraction from an area with few nerve endings in the technique described and using an energy source with low vertical and thermal diffusivity as the energy source.

Keywords: Clitoral Hoodoplasty; J-Plasma; Minimal Invasive; Clitoral Hood; FSFI; FGSIS PT: Punch Tool; VSS: Vancouver Scar Scale; PDO: Polydioxanone.

Abbreviations

FGSIS: The Female Genital Self-Image Scale; FSFI: Female Sexual Function Index; CO₂: Carbon Dioxide.

Introduction

Mucocutaneous tissue, covering the clitoral body and glans like a hat, is called as the prepuce or the clitoral hood [1]. Clitoral hood

protects the glans clitoris from irritation and hyperarousal. Excessive mucocutaneous tissue in the horizontal or vertical plane causes the clitoral hood to fold and the clitoral glans to close. Covering the glans clitoris with prepuce causes both a cosmetic problem and a decrease in clitoral arousal by preventing the arousal of the clitoral glans. The most common form of excess tissue of clitoral hood is parallel to the midline in the way of an extra tissue fold extending

from the midline to the sides [2]. Although clitoral hoodoplasty is mostly performed simultaneously with labiaplasty, it is a cosmetic gynecological procedure that can also be applied alone. The studies have shown that clitoral hood and labium minus are completely different anatomical structures and their embryological origins develop from different structures [1]. This embryological difference should be taken into consideration during the reconstruction of clitoral hood and labia minora.

The importance of clitoris and clitoral hood for sexual sensitivity is highlighted in the genital anatomy and sexual function self-assessment reports. A neuro-anatomical study examining the fetal clitoris has revealed that the highest nerve density was situated in the dorsal direction of the clitoris and clitoral hood [3]. Thus, the technique applied in surgery is quite important in the maintenance of dorsal nerve plexus and sensitivity of clitoris.

J-Plasma is a multi-mode electrosurgery technology as an alternative to the traditional monopolar, bipolar, ultrasonic, or laser devices using helium gas plasma. J-Plasma, approved by Food and Drug Administration, seems to be an applicable alternative in sensitive surgeries requiring precise incision and coagulation, minimally invasive methods such as clitoral hood surgery with minimal thermal diffusivity for the surrounding tissues. The aim of the present study is to describe minimal invasive clitoral hoodoplasty technique using J-Plasma technology with an approach protecting nerve anatomy of clitoris and clitoral hood.

Material and Method

Eighty-two women participated in the present study between 2018 and 2020. The reasons for the patients to apply the clinic are the perception of cosmetic impairment due to the clitoral hood completely or almost completely covering the clitoral glans, experiencing clitoral arousal problems, failure to have sufficient clitoral orgasm, or failure to have clitoral orgasm, low sexual satisfaction, failure to reach sufficient wetness during sexual intercourse and feeling dryness and pain. Among the participants, those who underwent female circumcision, clitoroplasty, labiaplasty, or clitoral hoodoplasty operation due to the cultural order of the relevant society, were excluded from the study. Before the operation, consents of all the participants were obtained by signing a detailed consent

form. The study was conducted according to good clinical practice standards (ICH-E6) and the principles of Declaration of Helsinki.

With the J-Plasma® handpiece, an incision with a mean depth of 3-4 mm and a mean length of 2-3 cm is made in the sulcus between the clitoral hood and labium majus in such a way to be parallel to this line by leaving the lateral ending of the clitoral hood 1 mm more lateral top to bottom. This procedure is applied to the other sulcus in the same way so that the incisions will be combined together bilaterally at 12 o'clock position at the peak. Hemostasis control in the dissection area was done in the non-contact spray mode, that is called as plasma beam coagulation. After hemostasis control was achieved, the incision area was scanned via the same non-contact spray mode in order to provide tightening and lifting effect.

Using the J-plasma dissection mode, a thin skin flap became released by being separated from the underlying tissue in the form of an isosceles triangle so that the 12 o'clock alignment will be the peak of the triangle. The underside of the released skin excision was scanned via the non-contract spray mode of the J-Plasma® handpiece and the hemostasis tightening and lifting effect was provided. The flap released from the clitoral hood was pulled upwards at 12 o'clock direction by holding with a blank forceps. After 1/3 of clitoral glans is adjusted to be remain outside and the remaining part will remain inside together with the clitoral hood, even though each margin of the excess tissue V of the flap left in the superior varies according to patient and tissue, it is marked as an inverted V by using a sterile skin pen with a mean value of average 0.7-0,1 cm, and the tissue is removed by performing an inverted V incision. Peak of the flap will correspond to the starting point of the incision and the suture node is joined in such a way to face inwards of the skin. Adsorbable monofilament poly(glycolide-co- caprolactone) 5/0 tekmon® was used as suture material. In order to prevent the formation of right and left subcutaneous tissue dead space, it is closed by the interrupted suture technique by using 3/8-sharp needle poly(glycolide-co-lactide), 4/0 Pegelak rapid® suture having a needle size of 16 mm. Skin is closed by continued suture technique with a 3/8-sharp needle poly(glycolide-co-lactide), 5.0 Pegelak rapid® suture having a needle size of 16 mm.

After the patient was taken to the room after the operation, ice

compress was applied to the surgical area as 30-min on and 45-min off, by making the ice not touching the skin directly. Patients were discharged from the hospital after 4-5 hour vital follow-up, general observation, and the bleeding control, and they were asked to continue ice compress at home. After the procedure, allergy histories of all the participants were asked and they were ordered En-fexia® (cefuroxime) 500 mg tablet as 2 x 1 for 5 days and Parol® (paracetamol) 500 mg tablet as 2 x 1 for 3 days. All exercises requiring compelling effort such as sexual intercourse, swimming in the sea and pool, running, heavy exercises, and competitive sports activities were prohibited for a month after the procedure. All patients were called for an early-period control on the 3rd and 7th postoperative days and for a late-period control in the 1st, 3rd, 6th, and 12th months. Early surgical complications were followed on the 3rd and 7th days, and late-period surgical complications were followed in the 1st and 3rd months. All the patients were assessed by The Female Genital Self-Image Scale (FGSIS) and Female Sexual Function Index (FSFI) before the surgery. After the surgery, all the patients were assessed again by using FSFI and FGSIS in the 6th and 12th months.

Results

While the mean age of the patients was 36.4 ± 5.2 , mean BMI was 25.8 ± 4.4 . On the 3rd-day control, edema in the clitoral hood in 3 patients, ecchymosis on the right incision line in 1 patient, unilateral suture opening in 1 patient, and wound site infection and flux in 1 patient were observed. After taking wound site cultures from the patients having wound site infection and suture opening, Klindan® 150 mg tablet (clindamycin) was started as 2x1 and a slight debridement was conducted to the subcutaneous skin of the patient having wound site opening by using lancet no.15 and then subcutaneous skin was interrupted after the application of Rif® 250 mg (Rifamycin SV Sodium) and the skin was closed with a continued suture. Culture results of wound site were reported as negative for both patients 48 hours later. Patients with edema were asked to continue the ice compress as 30-min on and 2-hour off for 2 more days and Lasix 40 mg tablet (Furosemide) 1x1 was started for 3 days. On the 7th day control, recovery in the surgical site of both patients, reduction in the edema of 3 patients, and regression in the ecchymosis were observed in the patient with ecchymosis. On the 7th day control, spontaneous clitoral arousal complaint was observed in 8 patients other than such patients.

It was observed that early period complications of the patients with suture opening, ecchymosis, edema, and wound site infection completely disappeared at the 1st month control. Unilateral clitoral hood dog-ear appearance was observed in 1 patient at the 1st month follow-up, however, the patient refused revision surgery. Of 8 patients having spontaneous clitoral arousal, 4 reported that this complaint disappeared. It was observed that the spontaneous arousal of the other 4 patients completely disappeared in the 3rd month.

All the participants were assessed by FSFI and FGSIS on the 6th and 12th months.

Female Sexual Function Index (FSFI) is a questionnaire including 6 subscales (desire, arousal, lubrication, orgasm, satisfaction, pain) and 19 questions that are filled by the participants. While minimum score is 2, maximum score is 36. In a study, FSFI was specified as the gold standard for the assessment of a therapeutically induced change in female sexual function [4]. Less than 26 points was accepted as an indicator of female sexual dysfunction [5].

Female genital self-image scale (FGSIS) was developed by Herbenick, *et al.* It is a quick and easy scale to measure the feelings of women toward their own sexual organs in a wide range including genital appearance and smell [6]. In FGSIS, consisting of seven items, each item gets a score between 1 and 4 points (strongly disagree 1 point, disagree 2 points, agree 3 points, and strongly agree 4 points). The higher the total score between 7 and 28 points, the more positive the genital area self-image perception.

In order to compare the pre-treatment, postoperative 6th-month, and postoperative 12th-month FSFI and FGSIS scores, 82 patients were evaluated prospectively.

Arousal and orgasm scores among the FSFI subscales increased in the postoperative 6th-month. This difference was statistically significant and the treatment significantly improved these parameters ($p < 0.001$). Also, the arousal score continued to increase in the 12th month significantly ($p < 0.05$). Although the orgasm score slightly decreased in the 12th month, this difference was not sta-

FSFI parameters	Pre-treatment (mean ± SD)	6 th month (mean ± SD)	12 th month (mean ± SD)
Sexual desire	4.2 ± 0.5	4.1 ± 0.6 ^z	3.9 ± 0.5 ^z
Arousal	3.1 ± 0.6	5.9 ± 0.4 ^x	6.4 ± 0.6 ^y
Lubrication	4.1 ± 0.5	4.1 ± 0.4 ^z	4.2 ± 0.5 ^z
Orgasm	4.3 ± 0.6	7.9 ± 0.8 ^x	7.7 ± 0.6 ^z
Satisfaction	3.6 ± 0.6	3.4 ± 0.7 ^z	3.5 ± 0.4 ^z
Pain	4.6 ± 0.6	4.2 ± 0.5 ^z	4.4 ± 0.7 ^z
Total Score	24.1 ± 1.5	29.4 ± 1.5 ^x	30.4 ± 1.7 ^z

Table 1: Comparison of the Female Sexual Function Index mean scores of the patients and the pre-treatment and post-treatment values.

^x:p < 0.001, ^y: p < 0.05, ^z:p > 0.05, SD: Standard Deviation, FSFI: Female Sexual Function Index.

FGSIS parameters	Pre-treatment (mean ± SD)	6 th month (mean ± SD)	12 th month (mean ± SD)
1	2.7 ± 0.7	3.4 ± 0.8 ^x	3.6 ± 0.6 ^z
2	3.4 ± 0.5	3.9 ± 0.4 ^y	3.9 ± 0.6 ^z
3	2.6 ± 0.6	3.4 ± 0.8 ^x	4.1 ± 0.7 ^x
4	2.3 ± 0.7	2.1 ± 0.4 ^z	2.3 ± 0.8 ^z
5	2.5 ± 0.7	2.4 ± 0.7 ^z	2.5 ± 0.4 ^z
6	3.1 ± 0.6	3.2 ± 0.7 ^z	2.9 ± 0.7 ^z
7	2.9 ± 0.4	3.3 ± 0.5 ^y	3.2 ± 0.7 ^z
Total Score	19.7 ± 1.8	21.9 ± 1.7 ^x	22.7 ± 1.8 ^y

Table 2: Comparison of the Female Genital Self-Image Scale mean scores of the patients and the pre-treatment and post-treatment values

^x:p < 0.001, ^y: p < 0.05, ^z:p > 0.05, SD: Standard Deviation, FGSIS: Female Genital Self-Image Scale.

tistically different from the 6th month (p>0.05). Scores of sexual desire, lubrication, satisfaction, and pain subscales did not show a significant difference in the 6th and 12th months (p>0.05). While the FSFI mean score obtained by summing the scores of FSFI subscales was 24.1 ± 1.5 in the pre-treatment period, this value increased to 29.4 ± 1.5 and 30.4 ± 1.7 in the 6th and 12th months after the treatment, respectively. The difference between the pre-treatment, post-treatment 6th month, post-treatment 12th month FSFI mean scores was statistically significant (p < 0.001 and p < 0.05, respectively) (Table 1).

Among the FGSIS parameters, 1st, 2nd, 3rd, and 7th parameters showed an increase in the post-treatment 6th month. This differ-

ence was statistically significant, and treatment significantly improved these parameters (p < 0.001 for 1st, 2nd, and 3rd parameters and p < 0.05 for 7th parameter). Among these parameters, scores of 1st, 2nd, and 7th parameters did not significantly change in the 12th month (p > 0.05). 3rd parameter continued to increase in the 12th month and this difference was significantly higher (p < 0.05). No significant change occurred in the 4th, 5th, and 6th parameters after the treatment (p > 0.05). While the FGSIS mean score obtained by summing the scores of FGSIS parameters was 19.7 ± 1.8 in the pre-treatment period, this value increased to 21.9 ± 1.7 and 22.7 ± 1.8 at the 6th and 12th months after the treatment, respectively. The mean score in two periods after the treatment was also significantly higher than pre-treatment period (p < 0.001 and p < 0.05, respectively) (Table 2).

Discussion

Clitoris and clitoris prepuce are one of the most important pleasure areas for the sexual life of women. In the surgeries applied to this area, it is recommended to know the neural network distribution of the area well, to prevent nerve damages and to remove the prepuce as little as possible during resection [7].

The goal of clitoral hoodoplasty operations is to uncover clitoral glans in closed and embedded position and stimulate easily it due to excess prepuce tissue. Some of clitoral hood is excised and lifting effect is also aimed.

The main neural network responsible for the arousal of clitoris is the dorsal nerve of the clitoris, that is the terminal branch of the pudendal nerve, which progresses along the dorsal edge of the clitoris as 2 main cords at 11 and 1 o'clock directions from the sulcus between the labium majus and clitoral hood [8]. Dorsal nerve of clitoris is a completely sensorial nerve and provides somatic innervation [9]. This nerve could not be observed at 12 o'clock direction. In their study Baskin, *et al.* observed no clitoris dorsal nerve or any nerve structure at 12 o'clock direction [10]. Also, in another clinical anatomy study, it was stated that the dorsal nerve of the clitoris progressed at 11 and 1 o'clock directions within the suspensor ligament, and the main nerve cord or neural network was not seen at the 12 o'clock direction [9].

The dorsal nerve of the clitoris can be accidentally injured during the suture placement in order to re-approximate the connective tissue after removing the prepuce and the vulvar skin in the lateral to the midline of the clitoral body or to provide hemostasis. Likewise, deep dissection in this site may cause nerve injury [11].

In their study, Placik, *et al.* reported that very deep progression should not be applied in the tissue during surgical dissection and procedures in order to prevent nerve destruction in labiaplasty and clitoral hoodoplasty operations [12]. The present study revealed the importance of minimal invasive superficial approach and minimal tissue removal once again.

In parallel with such publications, in the technique described in the study, no removal of lateral tissue is done in order to protect the lateral tissue by applying an incision with a superficial ap-

proach of 3-4 mm to the sulcus that is situated in the lateral to the clitoral hood.

There are different techniques applied for clitoral hoodoplasty. Hunter, *et al.* defined the Lateral vertically-oriented and Horizontally-oriented "inverted V" excision types [2]. In the defined V-excision type, the excision is usually performed cephalically up to the free edge of the hood, and according to the method explained, it is an incision extending to the lateral clitoral hood where the edges of the inverted V applied further below are wider. In the method described, making the inverted V incision from above requires less incision and less tissue removal when compared to the superior part because the edges of the V are shorter. When other studies are examined, it has been reported that the nerve is weak around the 12 o'clock direction. The fact that the peak of the inverted V-shaped incision corresponds to this area and the joining sutures are present here is thought to be advantageous for minimal invasive surgery and neuroprotective approach.

Alter, *et al.* defined the lateral and medial-lateral clitoral hood resection types [13]. In addition to these surgeries, they performed the central wedge resection labiaplasty operations in the same session. After the skin marking that was called as external hockey stick V, a large prepuce tissue was removed bilaterally with a lateral and medial approach. According to the technique defined, it suggests that this incision and tissue removal, which is larger and more lateral, may affect the clitoral sensitivity.

In the clitoral hoodoplasty techniques defined by Hunter, *et al.* it was recommended for the excision to be superficial in order to prevent negative affection on the clitoral sense in both lateral vertical excision and inverted V excision types [2]. Similarly, we think that a superficial approach should be shown without going too deep in the incision line.

Hamori, *et al.* removed the lateral tissue of the clitoral hood via the lateral triangular resection technique so that the scar tissue remained in the sulcus between the labium majus and the clitoral hood [14]. In the specified clitoral hoodoplasty approach, it is required to remove a relatively large tissue from top to bottom.

In the study where J-Plasma® energy was compared with conventional monopolar, bipolar, argon beam, and CO₂ laser devices on a pig model in terms of penetration depth and lateral thermal diffusivity, after J-Plasma® was applied to various types of tissue (bowel, bladder, peritoneal tissues), the tissues were examined histologically and it had minimal lateral and minimal vertical thermal diffusivity when compared to the tissue spread of other energy modalities [15]. In another study in which the implications for minimal invasive surgery were investigated, J-Plasma was applied to pig kidney, liver, ovary, uterus and muscle tissue for certain power modes and durations, and then the treated tissues were subjected to histological examination. As a result, it was specified that it had minimum lateral and vertical thermal diffusivity [16].

In another study, Parsa, *et al.* used J-Plasma® for the retroperitoneal dissection of ovarian endometrioma and specified that it could be used safely and aggressively in the treatment of the diseases adjacent to the vital organs due to its minimal lateral and vertical thermal diffusivity such as endometriosis [17].

Based on this point of view, J-Plasma® energy was used for dissection and surgical area hemostasis control via the technique defined. The studies reported that J-Plasma®, for which less lateral and vertical area thermal diffusivity was determined according to classical bipolar, monopolar, argon and CO₂ laser energy types, aims to obtain a fast wound healing and not to harm nerve by keeping away from underlying clitoris dorsal nerve.

It has an optimal contraction temperature range that will induce the restructuring effect of all kinds of collagen tissue in the collagen fibers without causing the thermal damage of the connective tissue. When the tissue reaches this temperature, tightening effect is achieved. When this temperature is exceeded, connective tissue damage is seen. Due to this tightening effect developed on the collagen tissue, J-Plasma® is used both for the facial and skin tightening and for shaping and tightening deeper soft tissues and fascia [18].

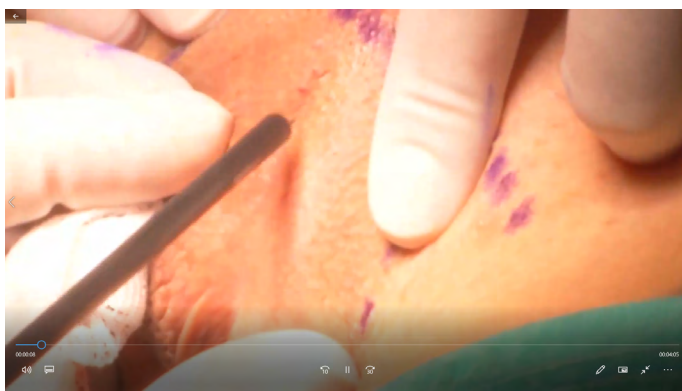
In another study, it was stated that hemostasis control of J-Plasma® is provided with coagulation mode, it was a surgical energy modality providing a tissue tightening effect by contracting and shortening fibroseptal bands in subcutaneous soft tissue due to energy, and contraction of soft tissue provided a slight tightening effect on skin above the tissue [19].

In the technique described, after using J-Plasma® for hemostasis in the lateral area and at the peak, such areas were scanned in the non-contact spray mode with J-Plasma® in order to generate tissue tightening and lifting effect. Simultaneously with the application of the procedure, a tightening effect was observed visually. Thus, there is no need to remove an extra lateral tissue or make a large incision for the clitoral hood lifting effect.

When the literature was reviewed, it was seen that after the clitoral hoodoplasty operation, the patients were not evaluated with FSFI or FGSIS, but they were generally analyzed by using the patient satisfaction questionnaires prepared by the surgical team.

Alter, *et al.* performed the wedge resection labiaplasty and clitoral hoodoplasty in the same session and sent a questionnaire, prepared by them, via mail to the patients 4 months later [13]. Parameters such as postoperative pain, self-confidence, quality of sexual life, and satisfaction with operation were evaluated via the questionnaire after the operation. FSFI and FGSIS that have been standardized and used in many previous scientific studies were used instead of using a scale or questionnaire prepared by us in order to understand how the technique affected the quality of the sexual life of women and female genital self-image perception. It was thought that it was more advantageous to measure the success or failure of the procedure by using the scales that have been standardized and included in the literature.

When the literature was reviewed, it was seen that after the clitoral hoodoplasty operation, the patients were not evaluated with FSFI or FGSIS, but they were generally analyzed by using the patient satisfaction questionnaires prepared by the surgical team.



Conclusion

The minimal invasive clitoral hoodoplasty technique described, which can be easily applied at the clinics using J-plasma technology, may be a new alternative procedure for clitoral hoodoplasty operations with its safety in the tissue with low horizontal and vertical energy spread and its positive statistical effect in the FGSIS and FSFI parameters. Longer-term follow-up results and randomized controlled studies are required.

Bibliography

1. Brodie K E., et al. "Study of clitoral hood anatomy in the pediatric population". *Journal of Pediatric Urology* 12.3 (2016): 177.e1-177.e5.
2. Hunter J G. "Labia Minora, Labia Majora, and Clitoral Hood Alteration: Experience-Based Recommendations". *Aesthetic Surgery Journal* 36.1 (2015): 71-79.
3. Wolffenbuttel K P., et al. "Clitoral hoodoplasty in females with disorders of sex development". *Journal of Pediatric Urology* 13.1 (2017): 61.e1-61.e5.
4. Sand, M., et al. "The female sexual function index (FSFI): a potential "gold standard" measure for assessing therapeutically-induced change in female sexual function". *Fertility and Sterility* 92.3 (2009): S129.
5. Wiegel M., et al. "The Female Sexual Function Index (FSFI): Cross-Validation and Development of Clinical Cutoff Scores". *Journal of Sex and Marital Therapy* 31.1 (2005): 1-20.
6. Herbenick D and Reece M. "Original Research—Outcomes Assessment: Development and Validation of the Female Genital Self-Image Scale". *The Journal of Sexual Medicine* 7.5 (2010): 1822-1830.
7. Schober J M., et al. "Self-assessment of genital anatomy, sexual sensitivity and function in women: implications for genitoplasty". *BJU International* 94.4 (2004): 589-594.
8. Vaze A., et al. "Determining the Course of the Dorsal Nerve of the Clitoris". *Urology* 72.5 (2008): 1040-1043.
9. Pauls RN. "Anatomy of the clitoris and the female sexual response". *Clinical Anatomy* 28 (2015): 376-384.
10. Baskin LS., et al. "Anatomical studies of the human clitoris". *Journal of Urology* 162 (1999): 1015-1020.
11. Jackson L A., et al. "Anatomy, Histology, and Nerve Density of Clitoris and Associated Structures: Clinical Applications to Vulvar Surgery". *American Journal of Obstetrics and Gynecology* (2019).
12. Placik O J and Arkins J P. "A Prospective Evaluation of Female External Genitalia Sensitivity to Pressure following Labia Minora Reduction and Clitoral Hood Reduction". *Plastic and Reconstructive Surgery* 136.4 (2015): 442e-452e.
13. Alter G J. "Aesthetic Labia Minora and Clitoral Hood Reduction Using Extended Central Wedge Resection". *Plastic and Reconstructive Surgery* 122.6 (2008): 1780-1789.
14. Hamori C A. "Postoperative Clitoral Hood Deformity After Labiaplasty". *Aesthetic Surgery Journal* 33.7 (2013): 1030-1036.
15. Salome M., et al. "Comparative Thermal Effects of J-Plasma®, Monopolar, Argon, and Laser Electrosurgery in a Porcine Tissue". *Surgical Technology International* 34 (2019): 35-39.
16. Jasmine P., et al. "Thermal Effect of J-Plasma® Energy in a Porcine Tissue Model: Implications for Minimally Invasive Surgery". *Surgical Technology International* 30 (2017): 19-24.
17. Parsa M. "Retroperitoneal Dissection of Ovarian Endometrioma Using J-Plasma Technology". *Journal of Minimally Invasive Gynecology* 22.6 (2015): S140.
18. Gentile R. "Cool Atmospheric Plasma (J-Plasma) and New Options for Facial Contouring and Skin Rejuvenation of the Heavy Face and Neck". *Facial Plastic Surgery* 34 (2018): 066-074.
19. Gentile RD. "Renuvion J-Plasma for Subdermal Skin Tightening Facial Contouring and Skin Rejuvenation of the Face and Neck". *Facial Plastic Surgery Clinics of North America* (2019).

Assets from publication with us

- Prompt Acknowledgement after receiving the article
- Thorough Double blinded peer review
- Rapid Publication
- Issue of Publication Certificate
- High visibility of your Published work

Website: www.actascientific.com/

Submit Article: www.actascientific.com/submission.php

Email us: editor@actascientific.com

Contact us: +91 9182824667