



Rehabilitation of Partially Edentulous Patient using Implant-Supported Fixed Prosthesis

Yosra Gassara^{1*}, Sarra Nasri², Belhassen Harzallah³, Mohamed Ben Khelifa⁴, Mounir Cherif⁵ and Dalenda Hadyaoui³

¹Department of Fixed Prosthodontics, Research Laboratory of Occlusodontics and Ceramic Prostheses LR16ES15, Faculty of Dental Medicine, University of Monastir, Monastir, Tunisia

²Department of Fixed Prosthodontics, faculty of dental medicine, University of Monastir, Monastir, Tunisia

³Professor, Department of Fixed Prosthodontics, Faculty of dental medicine, University of Monastir, Monastir, Tunisia

⁴Professor; Head of Department of Dentistry Hospital Fattouma, University of Monastir, Monastir, Tunisia

⁵Professor, Head of Department of Fixed Prosthodontics, Faculty of dental medicine, University of Monastir, Monastir, Tunisia

***Corresponding Author:** Yosra Gassara, Department of Fixed Prosthodontics, Research Laboratory of Occlusodontics and Ceramic Prostheses LR16ES15, Faculty of Dental Medicine, University of Monastir, Monastir, Tunisia.

Received: April 01, 2019; **Published:** May 23, 2019

Abstract

Background: The most common reasons for losing teeth are tooth decay, periodontal disease, or injury. Missing teeth can affect the esthetic, the oral function and lead to further dental complications.

Several treatment modalities were used to replace missing teeth and to avoid tooth shift and bone loss.

Implant-supported fixed prosthesis has provided an available treatment alternative for rehabilitation of patients with partially or fully edentulous. This treatment offer esthetic appearance, eliminate the discomfort of removable dentures and improve function and self-esteem.

Case Presentation: A patient was referred to the fixed prosthodontic department to replace his missed mandibular teeth with implant-supported prostheses. He refuses the removable prostheses even as a temporary solution. He has defective crowns on the 44, 45 and 31. The 31, 32 present a mobility degree 3. The decision was to place two implants on the right posterior sector and an implant on the left posterior sector; two immediate implants on the site of the 31, 32 and a delayed implant on the site of the 43.

Conclusions: Prosthetic rehabilitation of partially edentulous patients with implant-supported prostheses has many advantages such as fixity, good resistance and psychological comfort for the patient. However, it is important to respect the design, biomechanical, esthetic and occlusal requirements to obtain a satisfactory result.

Keywords: Dental Prosthesis; Implant-Supported; Dental Implants; Dental Occlusion; Cone-Beam Computed Tomography

Background

The most common reasons for losing teeth are tooth decay, periodontal disease, or injury. Missing teeth can affect esthetics, oral function and lead to further dental complications [1].

Several treatment modalities were used to replace missing teeth and to avoid tooth shift and bone loss.

Traditionally, removable partial dentures are an affordable and effective treatment option for partial edentulism [2], and there are three types which are indicated depending on the clinical situation and the dento-periodontal state:

- Dentures with cast metal frameworks en dentures with cast metal frameworks
- Acrylic tissue-supported dentures
- (semi)precision attachments [3].

However, removable prosthesis have shown many disadvantages such as lack of denture retention and stability, loss of bone, decreased masticatory efficiency and an anesthetic appearance due to the presence of clasps [2,4].

Thus, Implant-supported fixed prostheses has provided an available treatment alternative for rehabilitation of patients who

are partially or fully edentulous. This treatment offers esthetic appearance, eliminates the discomfort of removable dentures and improves function and self-esteem [5].

The prosthetic rehabilitation of partially edentulous patients involves evaluation of clinical aspects such as type of occlusion, vertical dimension, orientation of the occlusal plane, presence of functional or skeletal deficits, free-way space, size, number and location of edentulous areas [6].

Therefore, radiological evaluation of bone support using a radiological guide is important in these cases.

In addition to that, the study models should be positioned on articulator and should be waxed-up to evaluate the space between the residual ridge and the opposing occlusal plane. The choice for screw or cement retention depends on this space.

The surgical sequence is very delicate and the use of a surgical guide may facility this step by the orientation of the fixtures.

This article aims to present a clinical case describing surgical and prosthetic sequence of rehabilitation of partially edentulous patient using implant-supported fixed prosthesis.

Case Presentation

A 62-year-old patient with unremarkable medical history visited the fixed prosthodontic department to replace his missed mandibular teeth with implant-supported prostheses. The patient refuse the removable prostheses even as a temporally solution (Figure 1).

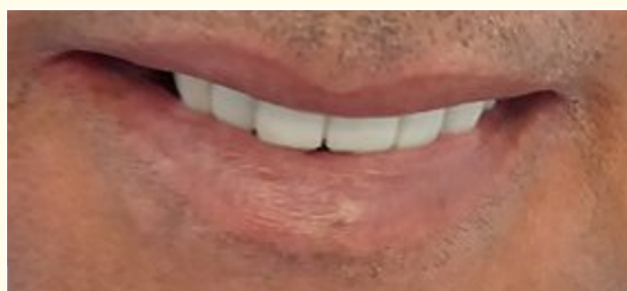

Figure 1: The initial smile.

Clinical examination revealed sufficient mouth opening (Figure 2) with poor oral hygiene, two defective crowns on the 44 and on the 45, the 33 was restored, the 31, 32 present a mobility degree 3. The 33, 44 and 45 presented an endodontic treatment (Figure 3,4).

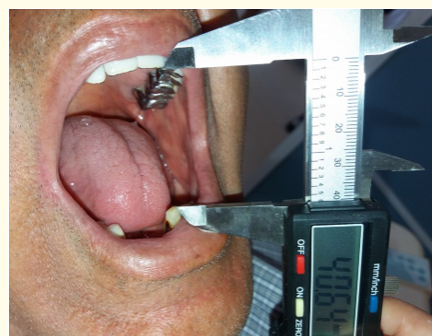

Figure 2: Amplitude of mouth opening.

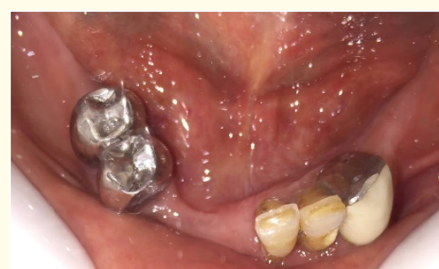

Figure 3: Edentulous crest.

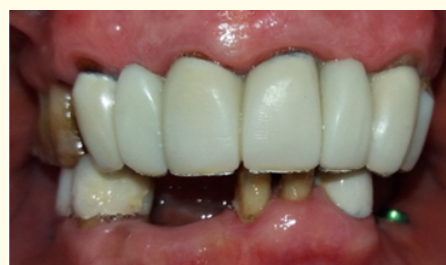

Figure 4: The occlusion of the patient.

Manufacture of the radiological template guide (Figure 5).

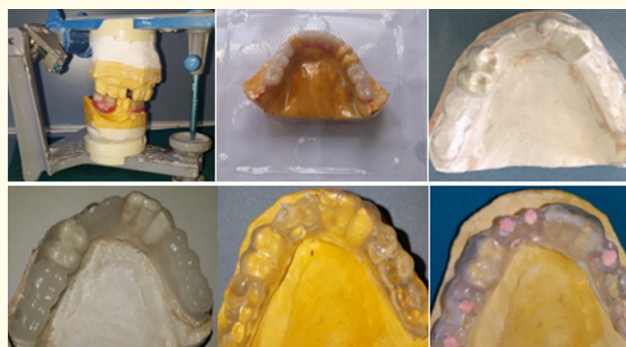

Figure 5: Steps of performing a template guide with gutta-percha.

The purpose of the radiological template guide is to give a visual representation of the future implant ideal positioning in imaging.

First, the study models were positioned on articulator, a wax-up was done according to the patient’s occlusion and the inter-arch relationship. Then, a splint was prepared using a thermoforming foil and flared by a transparent resin; all of them are placed on the mini-major. When firing was achieved, perforations were done in the central areas of the molded in wax-up template and were directed to the central axis of the crowns. Finally, an x-ray contrast material was placed. For this purpose, metal cannulas, a gutta-

percha, x-ray contrast plastics or varnish may be used. In our case, the perforations were filled by the gutta-percha.

The radiographic evaluation Cone Beam Computed Tomography (CBCT) using a Template guide with gutta-percha (Figure 6) showed adequate height and width of bone at posterior sites which confirms the feasibility of implant placement in the posterior edentulous ridge. It revealed an adequate bone of type 2 quality in the posterior sites according to the classification of Lekholm and Zarb.

The decision was to place two implants on the right posterior sector and an implant on the left posterior sector (Table 1).

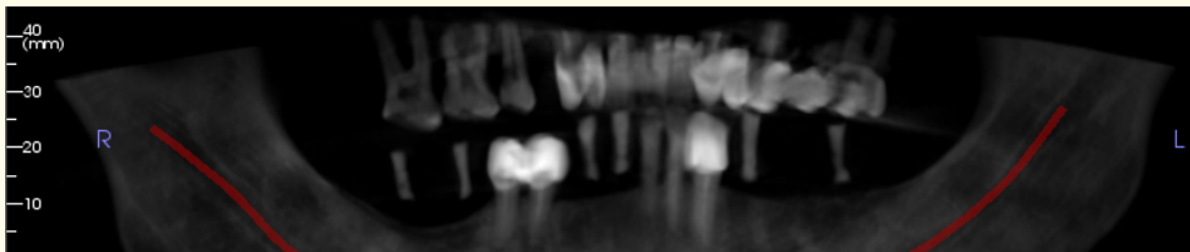


Figure 6: Radiographic evaluation of bone (CBCT).

	Implant on the site of the 46	Implant on the site of the 35	Implant on the site of the 37	Implant on the site of the 43	Implant on the site of the 32	Implant on the site of the 31
Diameter (mm)	4	4	4	3,4	3,4	3,4
Length (mm)	8	10	10	12	12	10

Table 1: Dimensions of implants.

However, there was an alveolar ridge resorption on the anterior sector.

The 31 and 32 present an insufficient bone support, the crown-to-root ratio was >1, the extraction was indicated and the decision of placing two immediate implants on the site of the 31, 32 and a delayed implant on the site of the 43 was retained.

The edentulous ridges were measured and the dimensions of implants were chosen.

The surgical and the prosthetic procedures were discussed in details and the patient signed an informed consent for a definitive implant-supported fixed prosthesis.

First, posterior implants were placed, after administration of local anesthesia with a 2% lidocaine hydrochloride solution containing epinephrine at 12.5 ug/ml, a flapless technique was used.

The X-ray guide was transformed to a surgical guide (Figure 7) and it was used when drilling the implant site, to check the orientation of the fixture. Three implant fixtures (drive system; 2 implants diameter 4 mm; Length 10 mm and 1 implant diameter 4 mm; Length 8 mm) were then placed. Initial stability was very good.

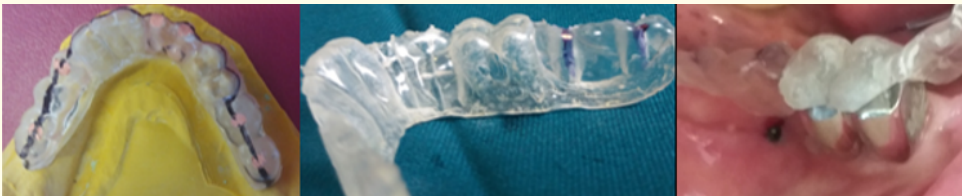

Figure 7: Implant placing using a surgical guide.

During the healing period, none of neurological symptoms, mobility, pain, swelling, or suppuration was detected. Radiological control revealed an excellent osseo-integration.

Four months post-surgery, peri-implant soft tissues were arranged using healing screws during two weeks (Figure 8).

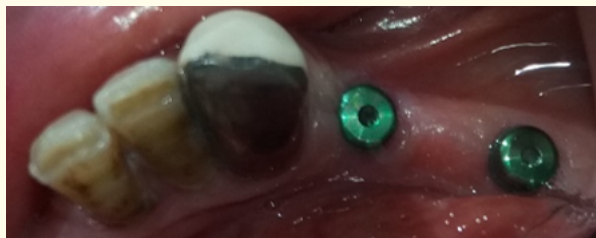


Figure 8: Healing screws.

Prosthetic treatment was done sector by sector. To achieve the bridge restoring # 44,45,46, an impression using the pick-up technique was made (Figure 9). Cast models were positioned on articulator (Figure 10). Then the metallic framework was performed (Figure 11). Some parameters should be respected for the occlusal morphology as a narrow occlusal table. After veneer layering referring to the corresponding shade matching the bridge was checked intraorally. As regard the occlusal concept, group-function occlusion, and mutually protected occlusion for the natural teeth, and the implant-protected occlusion for implant-supported prostheses, were controlled. Anterior guidance and disclusion of posterior teeth should be achieved on lateral excursion. Initial occlusal contact should occur on the natural teeth. The centric contacts were adjusted with light occlusal contact on the implant-supported prosthesis. Finally, the bridge was cemented using a “soft” cement (Figure 12), clinical care was given to the elimination of cement excess to avoid peri-implantitis.

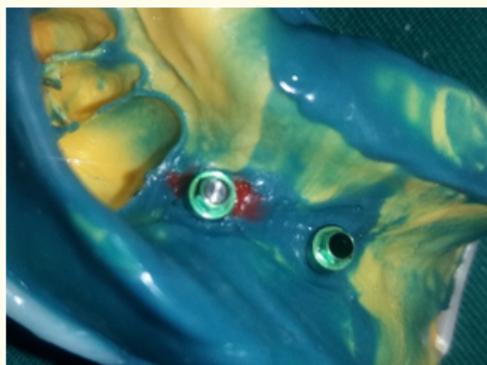


Figure 9: Master impression.



Figure 10: Cast models were positioned on articulator.

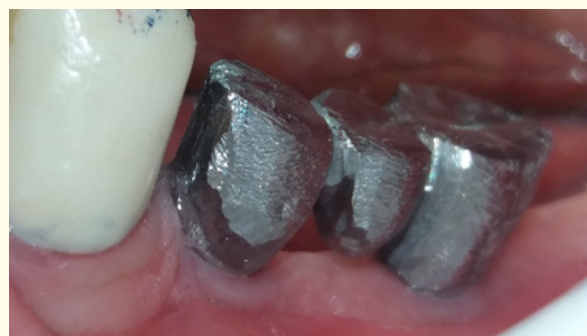

Figure 11: The metallic framework

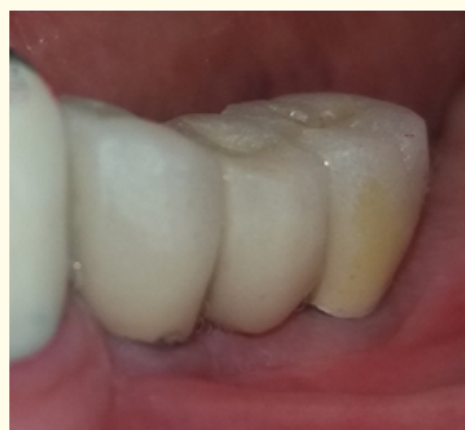

Figure 12: Cementation of the bridge.

For the left sector same steps were done, an accurate impression using the mixed Pick-up technique was performed with the framework of teeth # 34, 35. After that prosthetic treatment was completed (Figures 13,14).

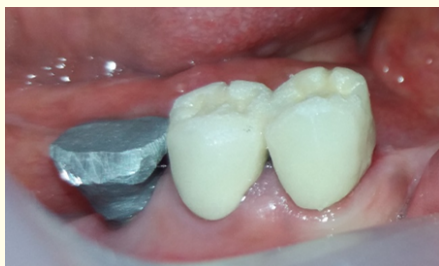

Figure 13: The metallic framework.

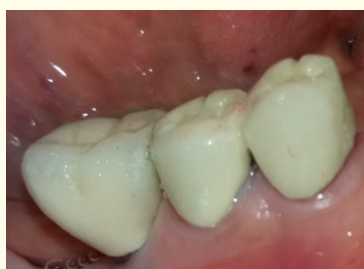

Figure 14: Cementation of two crowns on the 34, 35 and an implant supported crown on the 36.

Finally, the anterior sector was restored, a delayed implant and two immediate implants were placed after extraction of the 31, 32. Final restoration was performed and cemented (Figure 15).

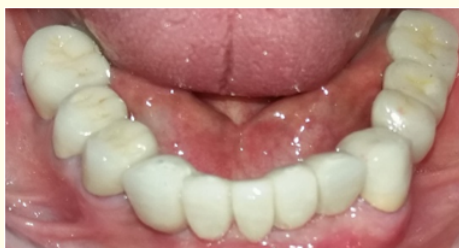

Figure 15: Final prostheses.

A follow up program was carried for the patient. It offers the opportunity to examine the patient every 3 months in the first year, after that once in the year (Figure 16).

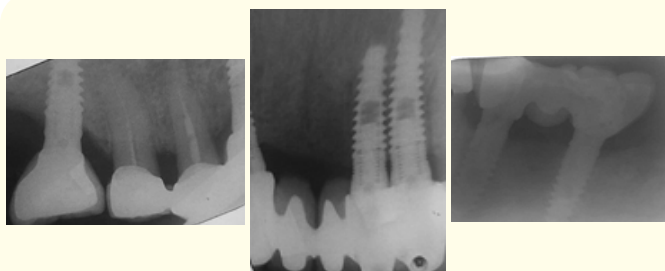


Figure 16: Post operative 3-6 months radiography.

Discussion

Implant-supported fixed prosthesis have made treatment options available to partially edentulous patients who previously may not have been able to benefit from fixed dental prosthesis because of the absence of sufficient abutment teeth.

This treatment modality allows replacing missing teeth and returning function and esthetic appearance.

Traditionally, the design, the number and the arrangement of implants were largely determined by bone topography and the location of adjacent and opposing teeth [7].

The space between the residual ridge and the opposing occlusal plane should be evaluated to choose between screw or cement retention. This space should be of 7 mm when replacing premolar and molar with cemented restoration [8].

In cases with minimal interocclusal space, achieving adequate retention is very difficult. According to Jivraj S, a 4 mm of space from the implant fixture to the occluding surface of the opposing dentition may be sufficient for the use of screw-retained restorations without need of preprosthetic surgery to gain more interocclusal space [9].

The radiological evaluation of bone support using a radiological guide is important in cases where multiple implants would be placed.

The radiological template's purpose is to give a visual representation of the future implant referring to ideal positioning in imaging [10].

When multiple teeth are missing in posterior quadrants, two or three implants may be required. The number of implant depends on bone quality and quantity, also on the biomechanics of the prosthesis and how load is distributed. Using three implants allow to offset implants and position them in tripoding. This has been referred to give a more optimal bone support than an absolute linear arrangement [11].

Nevertheless, the placement of three implants in a tripod effect is very difficult, to a certain degree, and is not always likely to occur. Therefore, if only two implants are placed, a wider diameter implant will be required to provide an equivalent benefit to the non linear configuration [8].

Additionally, to reduce mechanical complications, a well-adjusted and maintained occlusion is required. In fact, occlusion plays an important role in the biological and functional aspects of

the implant supported fixed prosthesis. A mal-controlled occlusion could lead to the fracture of veneering porcelain, decementation, screw loosening, abutments fracture or implant fracture, which could affect the longevity of the prosthesis [12,13].

The occlusal concepts of the implant supported fixed prosthesis has been derived from the occlusal concepts of traditional tooth borne restorations.

Concerning the occlusal morphology some details should exist as a narrow occlusal table, that is recommended to be reduced of 30 to 40 % for molars in order to increase axial loading and reduce stress on the implant and the implant/ abutment interface by decreasing nonaxial loading for the implant supported restorations. There are other recommendations including shallow occlusal anatomy, reduced cuspal inclination and flat fossa and grooves for wide freedom in centric [12].

The concept of group-function occlusion, and mutually protected occlusion for the natural teeth, and the implant-protected occlusion for implant-supported prostheses, aims to protect the implants by decreasing occlusal force on implant [14].

Finally, the implant-supported fixed prosthesis can restore not only the function but also the aesthetics. Thus, in our case, the use of cemented retained restoration is preferred over screw retained restorations since the occlusal surface is visible on the postero-inferior sector.

However, with this technique abutment screws must stay tight since a loose screw cannot be easily accessed and any future treatment cannot be affected. Therefore, temporary cements have been recommended to facilitate the removal of the prosthesis [8].

Conclusion

Prosthetic rehabilitation of partially edentulous patients with implant-supported prostheses has many advantages such as fixity, good resistance and psychological comfort for the patient. However, it is important to respect the design, biomechanical, esthetic and occlusal requirements to obtain a satisfactory result.

Bibliography

1. Louisa Christy Lunardhi. "Replace the Missing Teeth with Implant or Dentures". *EC Dental Science* 13.4 (2017): 162-167.
2. SB Khan and Geerts GA. "Aesthetic clasp design for Removable partial dentures: A literature review". *SADJ* 60.5 (2005):190-194.
3. Creugers NH1 and de Baat C. "Removable partial dentures. Oral functions and types". *Ned Tijdschr Tandheelkd* 116.11 (2009): 587-590.
4. Al-Dwairi ZN., *et al.* Awareness, attitude, and expectations toward dental implants among removable prostheses wearers". *Journal of Prosthodontics* 23.3 (2014):192-197.
5. Sahar Elkholy and Mohamed Zaki. "Evaluation of the posterior edentulous area with implant supported removable partial denture versus implant supported fixed partial denture as treatment option for free end cases : a six months follow up study". *EDJ* (2012).
6. Col DSJ D'Souza and Lt Col Parag Dua. "Rehabilitation strategies for partially edentulous prosthodontic principles and current trends". *MJAFI* 67.3 (2011): 296-298.
7. Donald F Reikie. "Esthetic and functional considerations for implant restoration of the partially edentulous patient". *Journal of Prosthetic Dentistry* 70.5 (1993): 433-437 .
8. S Jivraj and W Chee. "Treatment planning of implants in posterior quadrants". *British dental journal* 201.1 (2006): 13-23.
9. Jivraj S. "Screw versus cemented implant restorations: The decision-making process". *Journal of Dental Implants* 8.1 (2018): 9-19.
10. Rosen Borisov. "Radiological templates and CAD/CAM surgical guides. A literature review". *Journal of IMAB - Annual Proceeding (Scientific Papers)* 22.3 (2016):1285-1295.
11. Rangert B., *et al.* "Bending overload and implant fracture: a retrospective clinical analysis". *The International Journal of Oral and Maxillofacial Implants* 10.3 (1995):326-334.
12. Yuan JC and Sukotjo C. "Occlusion for implant-supported fixed dental prostheses in partially edentulous patients: a literature review and current concepts". *Journal of Periodontal and Implant Science* 43.2 (2013): 51-57.
13. Ayesha Hanif, *et al.* "Complications in implant dentistry". *European Journal of Dentistry* 11.1 (2017): 135-140.
14. Misch CE and Bidez MW. "Implant-protected occlusion: a biomechanical rationale". *Compendium* 15.11 (1994): 1330, 1332, 1334.

Volume 3 Issue 6 June 2019

© All rights are reserved by Yosra Gassara., *et al.*