



Leucocytozoonosis in Chickens (Gallus Gallus Domesticus)

Ahmadov EI, Hasanova JV, Mammadova FZ, Samadova SO and Topchiyeva Sh A*

Institute of Zoology National Academy of sciences of Azerbaijan, Azerbaijan

*Corresponding Author: Topchiyeva Sh A, Institute of Zoology National Academy of sciences of Azerbaijan, Azerbaijan.

Received: January 07, 2019; Published: January 29, 2019

Abstract

In this study we 125 chickens (*Gallus gallus domesticus*) were examined for the presence of avian blood parasites during December - March 2017-2018. Chickens were selected from different localities of Baku, Azerbaijan. Among the investigated chickens, *Leucocytozoon* had lower prevalence rates (12.8 %, 16/125) for chickens. The *Leucocytozoon* species from birds is founded first time for Azerbaijan region.

Keywords: *Gallus gallus*; *Leucocytozoon*; Chickens

Introduction

Blood parasites have been studied since 1884. Avian haemoparasites are known to be pathogenic to domestic animals causing huge economic loss to poultry farms, by reduced productivity. *Leucocytozoon* is the largest and common blood parasite encountered in birds. The genus *Leucocytozoon* is divided into two subgenera, *Akiba* and *Leucocytozoon*.

Leucocytozoonosis have been found in chickens, quail. According to Valkiūnas *G. L. caulleryi*, *L. sabrazesi*, and *L. schoutedeni* were found in chickens. *Leucocytozoon macleani* have been found in quail and in chickens belonging to the order of Galliformes [1]. Atkinson and Van Riper (1991) noted that haemoparasites have been recorded in almost 70% of the avian species examined, although prevalence estimates may depend on the method used in their detection [2]. The majority of investigated leucocytozoids are transmitted by blood-sucking dipteran insects of the Simuliidae [3-6]. Many species of these parasites cause serious pathology in avian hosts, and some are responsible for lethal diseases in domestic and wild birds; therefore, they became objects of intensive investigation [3]. However, virulence of the great majority of leucocytozoids for avian hosts and vectors remain insufficiently investigated. Limited evidence suggests that, being relatively non-pathogenic in naturally adapted hosts, leucocytozoids might cause diseases when they switch to new avian hosts [5,6]. Due to the worldwide distribution of leucocytozoids, information on their diversity and

pathogenicity is important for conservation purposes. This is particularly true for diurnal raptors of the Accipitridae, many species of which are endangered, are prevalently parasitized with *Leucocytozoon* spp. worldwide [5,7], and suffer from *Leucocytozoon* spp. infections [8,9]. The purpose of our research was to examine chickens for the presence avian blood parasites.

Material and Methods

In this study 125 chickens (*Gallus gallus domesticus*) have been selected from different localities of Baku, Azerbaijan during 2015-2016. Blood was collected from chickens to determine the presence of haemoparasites. Among the 125 investigated chickens, *Leucocytozoon* had lower prevalence rates, 12.8 % (16/125) for chickens.

At least 100 Giemsa stained fields on each smear were examined Under AXIO SCOPE A1 (Carl Zeiss Jena) microscope for avian blood parasites. The species of avian blood parasites were determined as per their morphological traits [1].

Results and Discussion

Some authors considered that Hemoprotozoa are slightly pathogenic to chickens. However, blood parasites can cause subclinical and debilitating effects and depresses breeding poultry. The genus of *Leucocytozoonosis* is lower than that of other Hemoprotozoa in chickens. Hemoprotozoais widely distributed in many parts of the world [10].

We found that the *Leucocytozoon gametocyte* does not contain refractile pigment and changes the shape of the host cell. An elongate form and round form were observed in birds. The appearance of both round and elongated gametocytes evidenced that the *Leucocytozoon* is a pathogenic strain. In the present study we found only the elongated form of the blood parasite in chickens. Though both elongated and round forms were observed but there were more elongated forms.

In the present study, we obtained an unidentified species of *Leucocytozoon* from blood of investigated chickens. 16 chickens were found infected by *Leucocytozoon* sp. The gametocytes were found in fusiform host cells. The measurements of the macrogametocyte of *Leucocytozoon* sp. from blood smears of chickens were $10.4 \pm 0.3 \mu\text{M} \times 4.9 \pm 0.28 \mu\text{M}$. Invasion intensity ranged from 2 to 4 per 100 microscopic fields. The size of parasite nucleus was $3.3 \pm 0.13 \mu\text{M} \times 2.4 \pm 0.21 \mu\text{M}$.

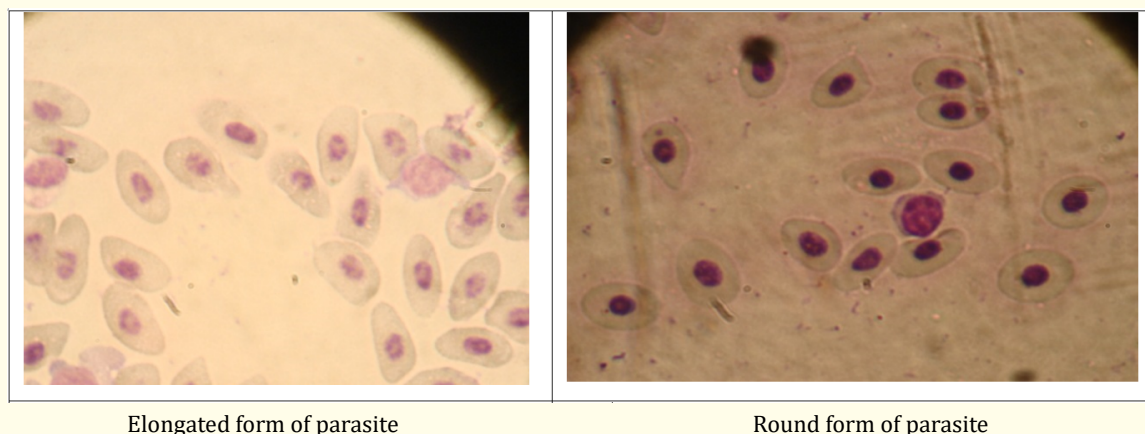


Figure 1: *Leucocytozoon* sp. in chicken, stained with Giemsa stain (100X).

The mature round gametocytes of *Leucocytozoon* sp. from of chickens were found in erythrocytes. The measurements of the macrogametocyte of *Leucocytozoon* spp. from blood smears of chickens were $14.6 \pm 0.3 \mu\text{M} \times 12.7 \pm 0.19 \mu\text{M}$. Invasion intensity ranged from 2 per 100 microscopic fields. The nuclear size of parasite was $3.75 \pm 0.13 \mu\text{M} \times 3.0 \pm 0.09 \mu\text{M}$ in measurement. The avian *Leucocytozoon* species was observed first time for Azerbaijan.

Conclusion

The present study is the first detailed description for the mature round and elongated form gametocytes of the of *Leucocytozoon* spp. in chickens. The morphological findings could be useful for identifying the species of avian blood parasites. The results demonstrate parasitized chickens with *Leucocytozoon*. The *Leucocytozoon* species from chickens was observed first time in Azerbaijan region.

Bibliography

1. Valkiūnas G. *Acta Zoologica* (2005): 379-393.
2. Fallon S, et al. *The American Naturalist* 165 (2005): 466-480.
3. Desser SS, et al. "The fine structure of *Leucocytozoon simondi*. I. Gametogenesis. *Canadian Journal of Zoology* 48 (1970): 331-336.
4. Bennett GF. "The genera *Leucocytozoon*, *Haemoproteus* and *Hepaticystis*". In *Parasitic protozoa* 2nd edition Academic Press, New York (1993): 273-307.
5. Valkiūnas G. "Avian malaria parasites and other haemosporidia". CRC Press, Boca Raton, Florida (2005): 946.
6. Forrester DJ and Greiner EC. "Leucocytozoonosis". In *Parasitic diseases of wild birds*, Blackwell Publishing, Ames, Iowa, (2008): 54-107.
7. Ashford RW, et al. "Leucocytozoon toddi in British sparrow hawks *Accipiter nisus*: Patterns of infection in nestlings". *Journal of Natural History* 25 (1991): 269-277.
8. Raidal SR and Jaensch SM. "Central nervous disease and blindness in nankeen kestrels (*Falco cenchroides*) due to a novel *Leucocytozoon*-like infection". *Avian Pathology* 29 (2000): 51-56.

9. Tarello W. "Leucocytozoonosis in falcons from Kuwait: Epidemiology, clinical signs and response to melarsomine". *Parasite* 13 (2006): 179.
10. Nath TC., *et al.* "A study on the presence of leucocytozoonosis in pigeon and chicken of hilly districts of Bangladesh". *Biological Sciences and Pharmaceutical Research* 2 (2014): 013-018.

Volume 3 Issue 2 February 2019

© All rights are reserved by Topchiyeva Sh A, *et al.*