



Ultra-Cavitation in the Treatment of the Cellulitis Evaluated by Ultrasonography

Pamplona AMM¹, Lopes KM¹, Meyer PF² and Santos-Filho SD^{3*}

¹Physiotherapist of the Universidade Potiguar – UnP, Brazil

²Professor of the Universidade Potiguar and Doctor in Health Sciences by UFRN, Brazil

³Professor of the Universidade Maurício de Nassau and Doctor in Health Sciences by UFRN, Brazil

***Corresponding Author:** Santos-Filho SD, Professor of the Universidade Maurício de Nassau and Doctor in Health Sciences by UFRN, Brazil.

Received: November 14, 2018; **Published:** November 23, 2018

Abstract

There are therapeutic proposals to the treatment of the cellulites (CL) in the field of the Dermatofuncional physiotherapy that are served to the public, although, few with effective results. Some therapeutic effects of the ultrasound in the CL are described as the increase of the tissue circulation, with improvement in the tissue injuries substances drainage. There are studies proving the high potential ultrasound effects, through of the cavitation phenomena, in the lipolysis of the adipose tissue. In front of the narrow relation between the CL and the adipose tissue and the possibility of evaluation this disease by ultrasonography, arise the interest in this study. The present work proposes to evaluate the ultra-cavitation treatment efficacy in the CL by ultrasonography exam. This research characterized as a study almost experimental, to the investigation of the effects of the ultra-cavitation. The sample was formed by 5 volunteers of female sex, with age range between 20 and 50 years old, put in one group of 5 individuals. The instruments utilized were the photogrammetry, the protocol of evaluation of the Cellulites and ultrasonography exam. It was utilized the Kolmogorov-Smirnov test and it was certificated the normality of the data used the T-paired test. It was showed improvement in the grade of the CL when the evaluation done by PEC, there was decreased in the fibrosis lines in the ultrasonography exam and observed increase in the adipose layers, though no significant alteration in the body weight of the patients, due to the small sample numbers, that demonstrated the no influence these variables in the results. It was seen yet that in the evaluation done by the evaluators there was significant difference between the grades initial and final of the CL in the evaluated group. It is also suggested to do this work again with a greater number of volunteers.

Keywords: Physiotherapy; Cellulitis; Ultrasound; Ultra-cavitation

Introduction

An increase number of women search to reach the society beauty pattern. In this search she submitted herself to plastic surgery, cosmetics treatments and nutrition diet purpose. The cellulites (CL) is an affection of great incidence in the population, been no desire for the patterns impose by the actual Society.

The CL start with an edematous stage, evolution of fibrosclerotic form. According with Afonso., *et al.* [1] and Cranendonk., *et al.* [2], the physiopathology of the CL is divided in four evolution stages, it will be: arteriolar pre-capillary sphincter alterations that induce venule-capillary permeability modifications, beyond of capillary stasis with transudation and pericapillary oedema between the adipocytes; The oedema makes metabolic alterations

that result in hyperplasia and hypertrophy of the reticular fibres and formation of irregular fibrotic plot, the collagen fibres of the septa polymerized between the adipocytes forming micronodules; progressive fibrosclerosis with formation of macronodules.

According yet with Nürenberger and Müller [3] the cellulitis classification it based in simple methodology, as well as, in variated grades, used until today, according the clinic presentation: Grade 0: without alterations of the cutaneous surface; Grade I: the affected surface area is plane when the person is lying or stand up, but the alterations can be viewed when it pinch the area with the fingers or under local muscle contraction; Grade II: orange or pillow skin look is evident when the subject is stand up without any manipulation (punch or contraction); Grade III: the described alterations in grade II are present and associate to supervening and nodulations [4].

According with Meyer [5], the Dermatofuncional physiotherapy acts in the CL using the lymphatic drainage, ultrasound, endermology and electrotherapy. Many therapeutic purposes are presented to the public, however few with effective results.

According with Pereira [6], the ultrasound is one of the principal's techniques of therapeutic treatment in the CL, it emits sound vibrations of high frequency that it will cause a friction in the cellular complex of tissue, create a micro-massage, by having a consequent increase of the cellular metabolism and broken of the CL [7].

In the chronic CL occurs the fibrosclerosis of the interlobular conjunctive septa. Therefore, the function of the treatment is to improve the tissue malleability. The use of the ultrasound is bound to the physiological effects associated to it capability of placement of substance through of the skin [8].

According Sant'Ana [9], the industry developed equipment directed to the aesthetics clinic, called high potential ultrasound that permits to treat a bigger area in little time of application and permits a better distribution of the acoustic and electrical energies by the tissues.

The high potential ultrasound also denominated High Intensity Focused Ultrasound (HIFU), through who's the energy is geometrically focused using a lent, or electronically to produce cavitation and heat. Other type of font of ultra-cavitation focus an energy with controlled profundity through of one pulse of not thermal wave. This differed of the first device cited that produce energy the adjustable profundity [10,11].

The ultra-cavitation is a technique that utilized the technology of Ultrasound to give target waves to break the fat cells without no effect on neighbour's tissue or organs [12].

This method consists of the formation of vapor bubbles in the interstitial zone of the conjunctive tissue that implode provokes shock waves that hurt selectivity the adipocyte membranes and release the stock fat. When this is liberty into blood current and is eliminated by lymphatic system and urinary via [13].

The effects of the ultra-cavitation in the adipocyte tissue are cited in the literature in some works, there is few articles that mention and prove the results of the ultra-cavitation in the treatment of CL, despite the relationship of this disease with adipocyte tissue alterations. Therefore, this study search to analyse the effects of this technique in CL through of an exam of ultrasonography and to verify if this resource will can be an option of treatment of this disease.

Methodology

Research characterization

This research constituted an experimental study, with evaluation pre and post therapeutic intervention. In this research was investigated the action of the ultracavitation in the FEG in women, through of photography, of evaluation protocol of the FEG and ultrasonography exam.

Population and sample

The population was constituted by women carriers FEG grades II and III that were interested in participating of the research.

The sample was constituted of 5 women, carriers FEG grade II and III, selected by criterions of inclusion and exclusion.

Criterions of inclusion and exclusion

The criterions of inclusion of the present project were volunteers of female sex, in the age between 20 and 50 years old, weight between 50 and 70 Kg, having FEG (grade II and III), could be multipara or nullipara, that could be doing use of anticonceptions and be sedentary, not showing sensitivity disorder, not be pregnancy, not be carrier of neoplasia, that presented acute inflammation, valvar insufficiency, not be carrier of hormonal disorder, like the hypothyroidism, hyperthyroidism, and mellitus diabetes that doing the use of medicine to lose weight.

The criterions of exclusion of the research were the patient give-up the treatment, refuse to do the exam or leave of the treatment for more than one week.

Instruments of data collection

The instruments utilized were the protocol of evaluation PAFEG (validate; [14]), digital photographic camera SONY 10.1 mega pixels, an equipment of ultrasonography MEDISON ACCUVIX V 10 with linear transducer, electro multi-frequential - 6 to 12 Hz, and for treatment were utilized the liposonic high power ultrasound, Meditea, Argentine (the equipment obey to the rules of the ISO 9001: 2008/ISO 13485: 2003/IEC 6060).

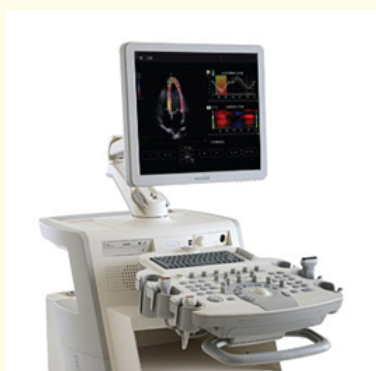

Photo 1: Equipment of ultrasonography of the MEDISON ACCUVIX V 10 with linear transducer.

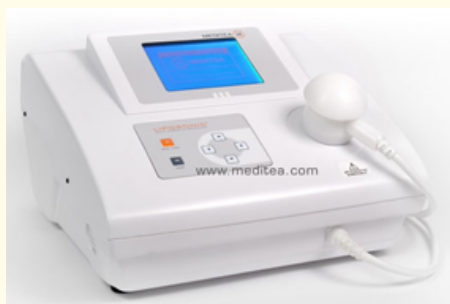

Photo 2: Equipment Liposonic High Power Ultrasound, Meditea.

Methods of evaluation

PAFEG

The protocol of evaluation of the FEG - PAFEG was developed for Meyer, *et al.* [14] and is formed by an anamnesis, a physical exam, the classification of the grade of FEG and a sensibility test.

This instrument is of easy application and permits classify, of adequate and objective form, the grade of FEG, as well as the levels of the sensitivity alterations when these were presents. So, the professional that utilized the PAFEG will have conditions of program a plan of treatment of manner more secure and efficient, respecting the particularity of each patient.

Photogrammetry

The photographic records were realized in well illuminate field, with no reflexive fund and preserving the individual's privacy. The volunteers were photographed in the orthostatic position, with arms elevated, by a digital camera Sony Cybershot, 12 megapixels, in relax. It was utilized the evaluation by photogrammetry, based in the study of Mendonça, *et al.* [15], when the photos were sent to 5 specialists to analyse in blind to evaluation of grades and treatment results.

Ultrasonography

The ultrasonography was realized by a specialist of the Clínica Serviço de Imagem Potiguar - SIP, with a ultrasound of the MEDISON ACCUVIX V 10 with linear transducer, electro multifrequency - 6 to 12 Hz, to mensuration of adipocyte tissue and of the fibrous septa, pre and post application of the ultracavitation.

This exam permit measures the distance between the skin and the fat and between the fat and the muscle by use acoustic waves that are transmitted through of the tissue. To assure the optimization of the ultrasonic energy, initial the patient must is stay in ventral position with pillows and cushions to help in the positioning. Delimited the area to be investigated with the patient in orthostatic position. The area marked was of 10 cm², the transducer was positioned of pending form, without make pression in the skin and it was dislocated about the treated area [12].

Proceeds

This project was submitted to the evaluation by Comitê de Ética em Pesquisa (CEP) da Universidade Potiguar (UNP), and sun before its approbation with the protocol number 129/2011 was developed.

It was realized the screening of the volunteers of the research, according with the criteria of inclusion of the sample, e the sample field. The same were clarified about the purposes, objectives, methodology and procedures to be adopted in the research. Through admission of each volunteer, it was applied the free consent and clarify term through of that the same authorized their participation in the research.

Before the clarify of the proceeds to the patients, they were submitted to an evaluation, according with the PAFEG [14] being delimited an area of 10 cm² of one of the glutes to demarcate the hit area with FEG, it was realized the photographic record of the area with the patient in orthostatic position and relax and in orthostatic position and contracting the muscle, also it was realized ultrasonography exam in the demarcate area.

Posteriorly, were initiate the applications with the ultracavitation, being applied in the area it was demarcated (10 cm²), the used intensity was of 30 watts, with 70% of potency during 10 minutes per demarcated area. Like this, it was realized six sections one per week, totalizing 1 month and half of treatment. To the end of the applications the patients were submitted to a new evaluation according with the protocol of FEG (PAFEG), it was repeated the photography record of the area with the patient in orthostatic position and relaxed and in orthostatic position and contracting the muscle, the patients were submitted to a new ultrasonography exam in the demarcate area. To guarantee of the experiment the evaluators of the pre and post-evaluation were the same.

Data analysis

To the data analysis was utilized the program Service Statistical Package for the Social Science - SPSS (version 19.0). The descriptive statistic was presented as tables, in that it was realized the absolute and relative frequency distribution to the ordinal's variables and the medium analysis, standard deviation and standard error to the continuum quantitative variables. The verification of the data normality was made by the Kolmogorov-Smirnov test. As it was verified the normality of the data, it was utilized the following tests: paired t test to compare the values pre and post intervention protocol; to identify if there are differences in the group in the initial and final evaluations. To all the tests it was attributed the significant level of 5%. The digital photography was analysed separately, by 5 blind evaluators in relation to the research.

Results and Discussions

To the ultracavitation treatment in FEG it was measured the body weight and realized the application of the PAFEG, where it was evaluated the sensibility, pain to hold and grade of the FEG and of the ultrasonography, where it was evaluated the thickness of the fibrous septa and the adipocyte layer. All this data was described in tables that show the results between the obtained scored before and after treatment.

The patients (5 chosen with inclusion and exclusion protocols) were weight in the evaluation moment and weekly before of each session. Above is presented the table 1, with the initial and final weight of the patients.


Patient	Initial weight	Final weight
01	59 kg	59 kg
02	65 kg	65 kg
03	79 kg	79 kg
04	69 kg	68 kg
05	79 kg	80 kg

Table 1: Body weight of the patients before and after treatment.

According with the analysis of the table the body weight of the volunteers sustains the same without important alterations, when compare before and after the treatment with the ultracavitation, according with that is found in Silva, *et al* [16].

The data collected through of the evaluate protocol of FEG (PAFEG) was grouped and analysed in the form of graphics and tables as follow above.

According with the PAFEG, the FEG can be classified as mild (I), moderate (II) or serious (III) (Graph 1).



Graph 1: Classification of the Grade of FEG.

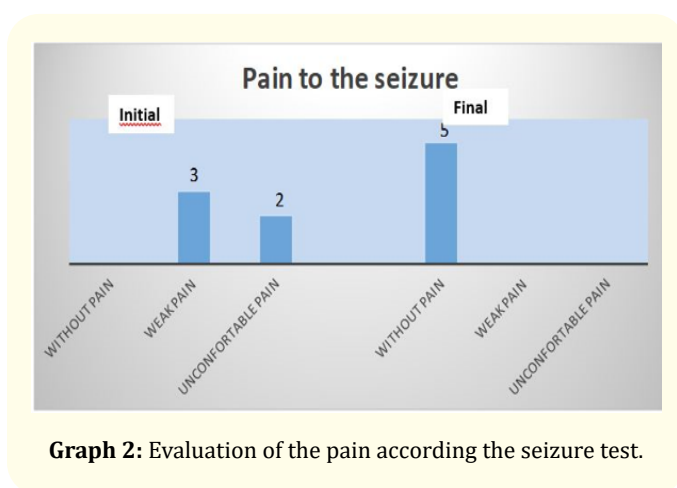
The group of evaluated women initially presented moderate grade predominance (60%), following by serious grade (40%). To the final of treatment had predominance of 60% to the moderate grade and 40% to the serious grade.

The PAFEG classify the FEG according with the appearance. In the grade Mid are detectable depressions and protrusions to the clamping test and/or to muscle contraction, in this grade there isn't increase of the pain sensitivity. In the moderate grade are detectable depressions and protrusions only to the inspection, there is increase of the pain sensitivity. Lastly, in the serious grade are detectable depressions and intense protrusions to the inspection and to the any position, in this grade there is also increase of the pain sensitivity [14,17].

It can observe that there isn't alteration in the grade of FEG of the evaluated volunteers as grade III by PAFEG. This fact can be explained by Ciporkin e Paschoal [18] at the first time and by Bani, et al. [19], because of point of view histologic the FEG is an oedematous infiltration of the subcutaneous subjunctive tissue, not inflammatory, followed of polymerisation of the fundamental substance, that, it infiltrate in the plots, produce a consecutive fibrotic reaction, that is, the Grade II the mucopolysaccharides that integrate it suffer a process of gelation. The therapeutic ultrasound is capable of reduce the viscosity of the exudates to open lymphatic canals and increase the circulation, that helps to reduce the oedema [20].

The tixotropic effect related to the ultrasound gives to him the capability of changes gel coloid in solution. This effect permits the increase of the tissue elasticity and the decrease of fibrotic tissue consistence, mainly in the cases of FEG [21]. Probably this explain why only the grade II evolved to I before the aplication of the ultracavitation, that use acoustic waves. In the grade III or sclerosis phase already has a hardening subcutaneous [22] and has major difficulty of answer to the treatment due the presence of fibrosis.

The graphic above represent the result of the evaluation done by PAFEG when the pain to seizure, before and after the treatment.



In the evaluated group, there was significant decrease of the pain sensibility to the seizure, when to the final of the treatment the total of the sample showed absence of pain to seizure. The evaluation of the sensibility is an important point of the PAFEG, we know that during the evolution of FEG the sensibility alters, demonstrating worsening. In the palpation is utilized the seizure test that evaluate the pain sensitivity quantify this as: without pain, poor pain, uncomfortable pain, distressing pain and torture pain [14].

Guirro e Guirro [17], affirms that there is increase of the local painful sensitivity of the FEG to the seizure test, moreover refer that if the pain sensation to be more bother than the normal, it is indicative of that already there alteration of the sensitivity, as result of the polymerization of the fundamental substance that, infiltrating in the plots, produce a fibrotic reaction. The pain to palpation occurs due to the increase of the vessels light and the adipocyte compresses the nerve cells. Due the nerve cells compression by adipocytes, there is a decrease of the tactile sensibility, because the mechanoreceptors in the epidermis are compressed, that compromise it performance.

In the PAFEG, the levels of sensitive alterations are evaluate by of the monofilaments of Semmes-Weinstein, at where the green monofilament (0.05g) indicates that the sensibility is inside of the normal limits, the blue monofilament (0.2g) indicates diminish soft touch, the purple monofilament (2.0g) indicates diminish protector sensation and loss the soft touch and the black red myofilament (4.0g) indicates loss of protector sensation and of the soft touch. In this study 100% of the sample presented normal sensibility.

According with Leite [23], in the FEG the conjunctive tissue stays distended and with that occurs the loss of the elasticity, the blood vessels light increase and occurs nervous compression that promotes pain to the palpation. Thus, the pain diminished to seizure, may have occurred due to the ultracavitation provokes temporary vasodilatation and increase the blood flux, and this mechanism have been proposed to explain the benefit effects in the temporary pain relief [24].

To evaluate the reproducibility, the photos were analysed alone by five examiners blind to research. The analysis was performed with base in a formulary sent to the evaluators with two photos, identified with before and after, the evaluators answered the questionings about of perception of result before the treatment, what the grade to the result and the classification of the grade of FEG (appendix 3). The authors realize the difficulty in classify the FEG through of the photos, then it was created a new classification with

base in the grades classify according Guirro e Guirro [17], at where the grades 2 and 3 were divided in soft, moderate and serious. During the research there was the loss of the photos of one volunteer, making with that the evaluation through of photo recorder it was only of 4 volunteers.

Mendonça, *et al.* [25] investigated the evaluation of FEG through of photo recorder, this study showed that the photogrammetry is satisfactory reliable when evaluated by one examiner in different occasions and by different examiners in an same photo recorder.

The blind evaluators give notes zero to ten to the obtained results with the treatment, according table 2.

The attributed notes by evaluators to the treatment results were satisfactory only for two patients, these patients that obtained better note of the evaluators, that is, improved the grade of FEG, hav-

Patient	Medium	Standard Deviation
01	3.8	3.27
02	5.8	2.3
03	7.4	1.51
04	6.9	1.74

Table 2: Notes of the patient treatment.

ing initially o FEG evaluated as grade II by PAFEG, and to the end of the treatment as grade I, which corroborate with the related by Lisboa, *et al.* (2003), when he affirms that in cases of fibrosis, the ultrasonic energy could be utilized as supporting in the decrease of these increasing the time of application and intensity.

The table 3 shows the statistic of the grade of FEG in the volunteers A, B, C and D before and after ultracavitation treatment.

Patients	Grade	Initial grade		Final grade	
		Absolute Frequency	Relative Frequency (%)	Absolute Frequency	Relative Frequency (%)
A	Soft	-	-	-	-
	Moderate	4	80.0	5	100.0
	Serious	1	20.0	-	-
	Total	5	100,0	-	-
B	Soft	-	-	-	-
	Moderate	2	40	5	100
	Serious	3	60	-	-
	Total	5	100	5	100
C	Soft	-	-	1	20
	Moderate	5	5	4	80
	Serious	-	-	-	-
	Total	100	100	100	100
D	Soft	-	-	-	-
	Moderate	3	60	4	80
	Serious	2	40	1	20
	Total	5	100	5	100

Table 3: Distribution of frequencies of the Grade of FEG of patients A, B, C and D.

In the table above we can observe that the volunteers A, C and D have the FEG evaluated initially as moderate, to the final of the treatment they were evaluated as moderate by more than 80%, we attribute this result to the related by Ronzio, *et al.* [26] where they affirm that the emission of high frequency ultrasound generates an increase of temperature, that corroborate with the relate by Ferraro, *et al.* [27] that shows that the ultrasound energy that is absorbed by tissue and make with that the molecular vibrations

result in a quickly increase in the temperature in focal zone, capable of destroy the adipocyte tissue and cause the contraction of collagen fibres.

The table 4 shows the statistic of subgrade of FEG of the patients A, B C and D, before and after the treatment of ultracavitation according the blind evaluators.

	Grade	Initial sub grade		Final sub grade	
		Absolute Frequency	Relative Frequency (%)	Absolute Frequency	Relative Frequency (%)
A	Soft	3	60	3	60
	Moderate	-	-	-	-
	Serious	2	40	2	40
	Total	5	100	5	100
B	Soft	2	40	2	40
	Moderate	3	60	1	20
	Serious	-	-	2	40
	Total	5	100	100	100
C	Soft	2	40	3	60
	Moderate	1	20	2	40
	Serious	2	40	-	-
	Total	5	100	5	100
D	Soft	-	-	-	-
	Moderate	3	60	4	80
	Serious	2	40	1	20
	Total	5	100	5	100

Table 4: Statistic of Sub Grade of the FEG of the patients A, B, C and D.

In the table above there was improvement in the sub-grade of FEG of the patients B, C and D, we verify so that inside of the grades there is changes in the aspect of FEG.

In the volunteer’s ultrasonography exams, it was observed the surface of the skin, the measurements the adipose layer and the fibres septa thickness. According with Meyer, *et al.* [5], the skin ultrasonography is a scientific know technique to the evaluation of dermal and hypodermic structures, in the cases of FEG is a method quite known and has great utility. For having a fibrous dermal and hypodermic septa standard and intense dermal oedema, the FEG can be evaluate by ultrasonography exam.

The following table do a descriptive analysis of the medium of right adipocyte layer initial and final of the volunteers, through ultrasonography exam.

	Media	N	Standard Deviation	Standard Error
Initial right adipocyte layer thickness	4.19	5	0.839	0.377
Final right adipocyte layer thickness	4.48	5	0.644	0.284

Table 5: Descriptive analysis of the right adipocyte layer.

Through of descriptive analysis of initial and final adipocyte layer thickness we concluded that there was a discreet increase in adipocyte layer thickness. We know that the adipocytes cells are sustained together by a collagen fibres network, Moretti [28] related that the fibrous septa that traction the swollen zones, provoking the formation of intimate attachments between skin and deep tissues. Already Moranga, *et al* [24] relate that the adipocyte tissue and collagen are affected by high frequency ultrasound, we are concluding the increase in the adipocyte layer occurred with the destruction of the fibrous septa that traction the skin, because as it was described in the table 1 there was no significant increase of weight in the volunteers.

The table below verify the difference in the right adipocyte layer thickness before and after the ultracavitation treatment, verified in the ultrasonography exam.

According with the evaluation by ultrasonography there was no significant statistic difference between the right adipocyte layer thickness initial and final to the exam of ultrasonography, although it demonstrates the increase in the adipocyte layer at the final of the treatment. This data is not according with the relate of Coleman, *et al.* [10], that explain the ultrasonic waves create compression cycles that provokes negative pression creating an innumer-

	Difference Media	Standard deviation	Standard error	Confidence interval of difference	
				Minor	Major
Initial high adipocyte layer thickness	-0.214	0.529	0.236	-0.871	0.443
Final high adipocyte layer thickness	-0.90	0.4	0.417	0.4	0.4

Table 6: Verification of the difference of the right adipocyte layer thickness before and after of the application of the ultracavitation verified in ultrasonography.

able quantity of nanobubbles, that difference from conventional ultrasound, these nanobubbles accumulate energy and grow up to a size that it turned stables and implode in the interstitial fluid cavities in the adipocyte tissue, this effect can leave to the rupture of the fat cells.

The following figure exposes the ultrasonography exams, doing before and after the treatment with the ultracavitation in the bilateral gluteus region.

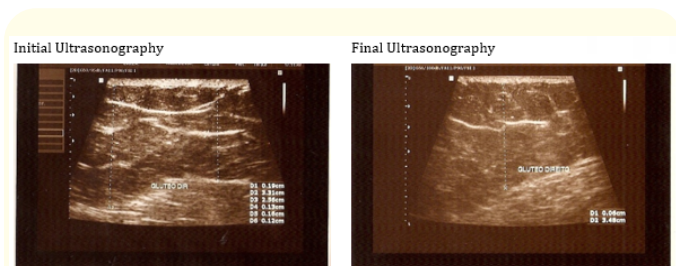


Figure 1: Evaluation by ultrasonography of the fat thickness and fibrous septa before and after the treatment with ultracavitation.

In the figures above, we observe the thickness of the adipocyte layer and the thickness of the fibrous septa. The media thickness of the adipocyte layer evaluated in the volunteers increase of 4.11 cm initially, to 4.38cm at the end of treatment with ultracavitation. We also observe that the media thickness of the fibrous septa evaluated in the volunteers, initially was 0.17 cm, at the end was 0.06 cm, still observed the decrease in the fibrous sept quantity.

The next table shows the descriptive analysis of the thickness of the adipocyte layer of the left buttock of the volunteers, before and after the treatment with ultracavitation and evaluated by ultrasonography exam.

	Media	N	Standard deviation	Standard error
Initial left adipocyte layer thickness	4.17	5	0.842	0.376
Final left adipocyte layer thickness	4.50	5	0.645	0.288

Table 7- Descriptive analysis of the thickness of left adipocyte layer on before and final of treatment with ultracavitation.

In the descriptive analysis of the left adipocyte layer before and after treatment there was a little increase in the adipocyte layer thickness.

The table below verify the difference in the left adipocyte layer thickness before and after the treatment with ultracavitation, verified in ultrasonography exam.

Through of ultrasonography exam was made the data analysis, it demonstrated that there was no statistic difference between the left adipocyte layer thickness before and after to the ultrasonography exam, although it demonstrate the increase in the adipocyte layer to the final of treatment, that match with the described by Teitelbaum (2007), when affirm that the alteration was attributed to the treatment by have not significative variations of the patient's body weight.

The table below verify the descriptive analysis of the variable results of right and left sept thickness before and after the treatment with ultracavitation, verified in the ultrasonography exam.

According with the ultrasonography exams, there was no significative difference in the reduction of the fibrous sept thickness. This fact can have occurred because the number of volunteers was much low, that can have diffculted the inferential analysis.

	Media difference	Standard deviation	Standard error	95% Confidence interval of the difference	
				Minor	Major
Initial left adipocyte layer thickness	-0.33	0.82	0.37	-1.36	0.69
Final left adipocyte layer thickness	-0.89	0.4	0.421	ND	ND

Table 8: Verification of the difference of left adipocyte layer thickness before and after of the application of ultracavitation verify in the ultrasonography

ND = no data.

However, Parizotto, *et al.* [29] consider the thinning of the fibres as a proliferation mechanism of collagen fibres as ultrasound effect, leading to present in the local fibres younger and with great probability of reduction of the tissue mechanical resistance [30-56].

Conclusion

Through this research, realized with the objective of investigate the effects of the ultracavitation in the FEG it was searched result quantitative and qualitative in relation to the grade of FEG, adipocyte layer and fibrous sept thickness.

The treatment with ultracavitation realized in the volunteers demonstrated improvement in the grade of FEG how much the evaluation done by PAFEG, there was decreased in the quantity and thickness of the fibrosis lines in the ultrasonography and it was observed increase in the adipocyte layer, although not have occurred significative alteration in the patient body weight, due to the small number of samples, that demonstrate the no influence of this variable in the results.

Therefore, it was suggested the realization of a study with similar methodology, with a great sample, the same parameters as time of application, dose and major number of applications to better confirmation of these results and proof of the ultracavitation efficacy in FEG.

Bibliography

1. Afonso João Paulo Junqueira M., *et al.* "Celulite: artigo de revisão". *Surgical and Cosmetic Dermatology* 2 (2010): 214-219.
2. Cranendonk DR., *et al.* "Cellulitis: current insights into pathophysiology and clinical management". *The Netherlands Journal of Medicine* 75 (2017): 266-378.
3. Nurnberger F and Muller G. "So-called cellulite: an invented disease". *The Journal of Dermatologic Surgery and Oncology* 4 (1978): 221-229.
4. Lipsky BA., *et al.* "A proposed new classification of skin and soft tissue infections modelled on the subset of diabetic foot infection". *Open Forum Infectious Diseases* 4 (2017).
5. Meyer PF., *et al.* "Efeitos das Ondas Sônicas de Baixa Frequência no Fibro Edema Gelóide". *Revista Brasileira de Terapias e Saúde* 1 (2011): 31-36.
6. Pereira C. "Fisioterapia na lipodistrofia ginóide. (2004).
7. Adhikari S and Blaivas M. "Sonography First for Subcutaneous Abscess and Cellulitis Evaluation". *Journal of Ultrasound in Medicine* 31 (2012): 1509-1512.
8. Miller D., *et al.* "Overview of therapeutic ultrasound applications and safety considerations". *Journal of Ultrasound in Medicine* 31 (2012): 623-634.
9. Sant'Ana EMC., *et al.* "Fibro Edema Gelóide (celulite): fisiopatologia e tratamento com endermologia". *Fisioterapia Especialidades* 1 (2007): 30-35.
10. Coleman KM., *et al.* "Non-Invasive: External Ultrasonic Lipolysis". *Seminars in Cutaneous Medicine and Surgery* 28 (2009): 263-267.
11. Lang BH., *et al.* "The efficacy and safety of high-intense focused ultrasound ablation of benign thyroid nodules". *Ultrasonography* 37 (2018): 89-97.

12. Hotta TA. "Nonsurgical Body Contouring with Focused Ultrasound". *Plastic Surgical Nursing* 30 (2010): 77-82.
13. Jens UQ., et al. "High Intensity Focused Ultrasound". *The European Aesthetic Guide Spring* (2010).
14. Meyer PF., et al. "Desenvolvimento e aplicação de um protocolo de avaliação fisioterapêutica em pacientes com fibro edema gelóide". *Fisioterapia em Movimento* 18 (2005): 75-83.
15. Mendonça KMPP., et al. "Ressonância magnética: um progresso na avaliação do Fibro Edema Gelóide". *Revista Fisioterapia Ser 2* (2007): 266-268.
16. Silva LPAP., et al. "Estudo de caso: EFEITO DA ULTRACAVITAÇÃO NA GORDURA LOCALIZADA Monografia (Especialização em Fisioterapia Dermato funcional) - Universidade Gama Filho. Salvador (2011).
17. Guirro EICO and Guirro RRJ. "Fisioterapia Dermato-funcional: recursos, patologias e fundamentos". 3. edition Barueri: Manole (2004).
18. Ciporkin H., et al. "Atualização terapêutica e fisiopatogênica da lipodistrofia ginóide (LDG): Celulite". São Paulo: Santos (1992).
19. Bani D., et al. "Histological and ultrastructural effects of ultrasound-induced cavitation on human skin adipose tissue". *Plastic and Reconstructive Surgery - Global Open* 1 (2013): e41.
20. Prentice WE. "Modalidades terapêuticas para fisioterapeutas". São Paulo: Artmed (2004).
21. Borges F. "Dermato-funcional: modalidades terapêuticas nas disfunções estéticas". São Paulo: Phorte (2006).
22. Ribeiro MC and Stefanello TD. "Tratamento Do Fibro Edema Gelóide Associando O Uso De Endermologia, Corrente Russa E Massagem Modeladora - Um Relato De Caso (2006).
23. Leite RG. "Fisioterapia dermatofuncional: uma área em observação". Work presented in (2003).
24. Moreno-Moraga J., et al. "Body Contouring by Non-Invasive Transdermal Focused Ultrasound". *Lasers in Surgery and Medicine* 39 (2007): 315-323.
25. Mendonça RS., et al. "As Principais Alterações Dermatológicas em Pacientes Obesos". *Arquivos Brasileiros de Cirurgia Digestiva* 24 (2011): 68-73.
26. Ronzio OA., et al. "Ultracavitação De Baixa Frequência: Estudo De Caso [Periódico]. - Natal: Catussaba, Revista Científica da Escola da Saúde - UNP (2012).
27. Ferraro GA., et al. "Histologic effects of external ultrasound-assisted lipectomy on adipose tissue". *Aesthetic Plastic Surgery* (2008).
28. Moretti EA. "Estudo macro e microscópico da fáscia superficial em membros inferiores: um conceito diferente sobre a cellulite". *Mesoterapia Atual* 1 (1997): 9-12.
29. Parizotto NA., et al. "Análise histológica em tecido epitelial sadio de ratos Wistar (in vivo) irradiados com diferentes intensidades do ultrassom". *Revista Brasileira de Fisioterapia* 14 (2010): 114-120.
30. Guimarães GN., et al. "Effect of ultrasound and dexpanthenol on collagen organization in tegumentary lesions". *Revista Brasileira de Fisioterapia* 15 (2011): 227-232.
31. Avram MM., et al. "Subcutaneous fat in normal and diseased states". *Journal of American Academy Dermatology* (2005): 663-670.
32. Bacelar V., et al. "Artigo revisão: Importância da vacuoterapia no fibro edema gelóide". *Fisioterapia Brasil* 7 (2006).
33. Baker KG., et al. "Review of Therapeutic Ultrasound: Biophysical Effects". *Physical Therapy* 81 (2001): 1351-1358.
34. Brandão DSM., et al. "Avaliação da técnica de drenagem linfática manual no tratamento do fibro edema gelóide em mulheres". *Conscientiae Saúde, Sao Paulo* 9 (2010): 618-623.
35. Brasil L. "Ultra Som Japonês". Disponível em: (2018).
36. Brown SA., et al. "Characterization of Nonthermal Focused Ultrasound for Noninvasive Selective Fat Cell Disruption (Lysis): Technical and Preclinical Assessment". *Plastic and Reconstructive Surgery* 124 (2009): 92-101.
37. Campos MSP. "Curso de fisioterapia estética corporal". set (2000).

38. Dubinsky TJ, et al. "High-Intensity Focused Ultrasound: Current Potential and Oncologic Applications". *American Journal of Roentgenology* (2008): 191-199.
39. Furini Jr, et al. "Ultra-som. (2018).
40. Godoy JMP, et al. "Celulite, do diagnóstico ao tratamento". São Paulo: Riocor (2003).
41. Guirro E and Guirro R. "Fisioterapia dermatofuncional: Fundamentos, recursos e patologias". 3. edition São Paulo: Manole (2002).
42. Johns LD. "Nonthermal Effects of Therapeutic Ultrasound: The Frequency Resonance Hypothesis". *Journal of Athletic Training* 37 (2002): 293-299.
43. Kede MV and Sabatovich O. "Aesthetic Dermatology". São Paulo: Atheneu (2004).
44. Kennedy, et al. "High intensity focused ultrasound: surgery of the future?" *British Journal of Radiology* (2003): 590-599.
45. Kim Young-sun, et al. "High-intensity focused ultrasound therapy: an overview for radiologists". *Korean Journal of Radiology* 1 (2008): 291-302.
46. Kuhnen AP, et al. "Efeitos Fisiológicos Do Ultra-som Terapêutico no Tratamento do Fibro-Edema-Gelóide. (2011).
47. Low J and Reed A. "Eletroterapia explicada: princípios e prática". 3 edition São Paulo: Manole, (2001).
48. Machado AFP, et al. "Incidência de fibro edema gelóide em mulheres caucasianas jovens". *Arquivos Brasileiros de Ciências da Saúde* 34 (2009): 80-86.
49. Menezes RC, et al. "Ultra-som no Tratamento do Fibro Edema Gelóide". *Revista Inspirar* 1 (2009): 10-14.
50. Monográfico. "Instituto Brasileiro de Medicina de Reabilitação (I.B.M.R.)". *Faculdade de Ciências e Saúde, Rio de Janeiro* (2003).
51. Oliveira ACS, et al. "Manual De Normalização Bibliográfica Para Elaboração De Artigo Científico". (2008).
52. Piérard GE, et al. "Cellulite: From Standing Fat Herniation to Hypodermal Stretch Marks". *American Journal of Dermatopathology* (2000): 34-37.
53. Rossi ABT and Verganini AL. "Cellulite: a review". *Journal of the European Academy of Dermatology and Venereology* (2000): 251-262.
54. Serra WS, et al. "Benefícios do ultra-som terapêutico no tratamento do fibro edema gelóide" (2012).
55. Smalls LK, et al. "Effect of Weight Loss on Cellulite: Gyrodystrophy". *Plastic and Reconstructive Surgery* 118 (2006): 510-516.
56. Spafisio. "Liposinic" (2012).

Volume 2 Issue 9 December 2018

© All rights are reserved by Santos-Filho SD, et al.