



Prevalence of Dental and Oral Diseases in People Living with HIV, A Systematic Review

Sheehama J^{1*}, Mwadinohamba I² and Lukolo L³

¹UNAM School of Medicine, Namibia

²MoHSS Namibia, Namibia

³UNAM Hage Geingob Campus, Namibia

*Corresponding Author: Sheehama J, UNAM School of Medicine, Namibia.

DOI: 10.31080/ASDS.2020.04.0989

Received: November 03, 2020

Published: November 27, 2020

© All rights are reserved by Sheehama J, et al.

Abstract

Introduction: This systemic review, of the prevalence of dental and oral manifestations in people living with HIV, was conducted from articles based on studies in various countries that aimed to establish the characteristics and prevalence of individual oral manifestations.

Methodology: The electronic retrieval systems and databases that were searched for relevant articles were PubMed and Google Scholar. A total of 41,237 articles were found on these sites, of which only 5 were included in the review. The five articles were selected based on the criteria of: articles published in English; studies carried out between January 2005 to November 2019 (recent data of less than 15 years); articles discussing only the prevalence of dental and oral diseases in people living with HIV. Exclusion criteria included articles that were more than 15 years old, that were focused on newly infected patients and articles that included other systemic diseases –such as Diabetes Mellitus- that could adversely affect oral health.

Results: According to the compiled results from all the reviewed articles, oral candidiasis and angular cheilitis were the most common oral manifestations, at 37% and 14.88% respectively. Oral Kaposi was noted to be the least occurring oral manifestation at 0.01%. Oral candidiasis was found to be the most common oral pathology, in both children and adults, in all articles reviewed.

Discussion: Based on the reviewed data collected by various studies, it is clear to see that evaluating oral health status of PLWH is very important at every stage in the management of HIV disease. All dental and oral lesions identified should be paid attention to, as most of these conditions are associated with immense pain and discomfort- this in return hinders the individuals ability to feed thus putting them at greater risk of malnutrition and eventually potential for opportunistic infections as they are not able to take medication and are generally unable to fend off infections. It is of utmost importance that health care providers be able to identify HIV-related oral manifestations, not only in the proper management of PLWH, but in also identifying HIV naïve patients. One major challenge of prevention of HIV, lies in HIV infected persons unaware of their status. A benefit of recognizing HIV-oral related diseases in such patients could thus assist with providing immediate health promotion and prevention possibilities. Hence, the importance of an integrated approach when dealing with PLWH should be sought.

Keywords: HIV; PLWH; Dental and Oral Diseases

Introduction

The HIV virus has been the main subject of scientific research since its identification in the 1980s, after it was understood that the virus had crossed over from chimpanzees to humans in what is today the city of the Democratic Republic of Congo [1]. Since then, new advances in pharmacology have seen the production of

medicines able to prolong the life of people living with HIV. Regardless of these advances, HIV still remains a public health concern in the developing countries of Africa and Namibia is no exception to this epidemic. The Namibian HIV prevalence has been stated to be amongst the highest in the world. In 2013, the Demographic and Health Survey reported a national adult population prevalence of

14% (CDC-Namibia, 2017). The latest HIV prevalence now stands at 16.9% (New Era, 2016).

It is alarming that individuals are still newly infected irrespective of the various campaigns that are centred on the prevention, management and treatment of HIV infections. HIV is a manageable chronic condition, but only in those who are aware of their diagnosis and start effective antiretroviral therapy early enough [2]. There are those individuals who are not aware of their diagnosis and as a result, succumb to various illnesses that are associated to untreated HIV. The main concern with HIV is that it cannot be cured and presents with various opportunistic infections. These infections include malignancies, respiratory and neurological diseases. It is also important to note that HIV presents with dental and oral diseases, which are often not considered when managing PLWH. These dental and oral diseases are most often as a direct result of untreated HIV infection but may also occur as a side effect of the antiretroviral medication. It is these omitted dental and oral diseases that are often a cause of pain and discomfort in PLWH.

This systematic review will assess the prevalence of the most common HIV-oral manifestations and thus provide the basis for the management of people living with HIV. Diseases of the oral cavity are amongst the earliest manifestations that can aid in identifying a potential HIV infected person, if we are knowledgeable about it. These dental and oral infections render the individual susceptible to more diseases, as they halt proper nutritional uptake.

Literature Review

HIV belongs to the Lentivirus group of the Retrovirus family. There are two occurring types, HIV-1 and HIV-2. HIV-1 is the most frequently occurring strain globally [2]. Retroviruses are characterized by the possession of the enzyme reverse transcriptase, which allows for the viral RNA to be transcribed into DNA and as a result, incorporated into the host cell genome. As stated by Kumar and Clark, the key driver of disease progression in HIV infected persons, is associated to the long-term inflammatory state of HIV (2012). The spectrum of illnesses associated with HIV infection is broad and is the result of direct HIV effects, the drugs used to treat the condition; HIV associated immune dysfunction and co-existing morbidity. Dental and oral mucous manifestations of HIV include oral candidiasis, oral hairy leukoplakia, oral herpes simplex, periodontal disease and oral warts [2]. Drug reactions with mucous manifestations are frequent- these manifestations include aphthous ulcers, which are severe and slow healing and as a result, impair the individuals' ability to eat.

Oral manifestations of HIV disease are common. Careful history taking and detailed examination of the patient's oral cavity are important parts of the physical examination. It has been stated that early recognition, diagnosis, and treatment of HIV-associated oral lesions may reduce morbidity; and that the presence of these lesions may be an early diagnostic indicator of immunodeficiency and HIV infection, may change the classification of the stage of HIV infection, and is a predictor of the progression of HIV disease (HIV Insight, 1998). Periodontal disease is a fairly common problem in both asymptomatic and symptomatic HIV-infected patients. It can progress to the rapid and severe condition called necrotizing ulcerative periodontitis. The presenting clinical features of these diseases often differ from those in non-HIV-infected persons (HIV Insight, 1998). NUP often occurs in clean mouths where there is very little plaque or calculus to account for the gingivitis. The onset is often sudden, with rapid loss of bone and soft tissue. Patients sometimes complain of spontaneous bleeding. NUP may present as rapid loss of supporting bone and soft tissue; teeth may loosen and eventually fall out (HIV Insight, 1998). Salivary gland disease associated with HIV infection can present as xerostomia with or without salivary gland enlargement. The etiology of HIV-SGD is as yet unknown but the enlarged parotid glands can be a source of annoyance and discomfort. Xerostomia is sometimes seen in individuals with HIV-SGD. HIV-infected patients may also experience dry mouth in association with taking certain medications that can hinder salivary secretion, such as the antiretroviral drug ddI used in HAART (HIV Insight, 1998). The evaluation of the oral health status of PLWH is important at every stage in management of the disease. Oral health professionals can contribute effectively to the control of HIV/AIDS through health education, patient care, infection control and surveillance [3].

The review carried out at the Vilnius University, Institute of Dentistry in Lithuania, found that oral lesions are amongst the earliest signs of HIV infection and for individuals with unknown HIV status may suggest possible HIV diagnosis; for persons diagnosed with HIV who are not yet on therapy, the presence of certain oral manifestations predicts progression to AIDS [3]. The study further states that for patients on HAART the presence of certain oral manifestations may serve as surrogate markers for the efficacy of antiretroviral therapy.

For many individuals, oral hygiene is not considered a priority. And in situations where HIV is being treated by continuous daily intake of drugs, oral health is the least of individuals worry. How-

ever, good oral hygiene is an important part of managing HIV infection. Due to the various conditions that can manifest orally and then ultimately lead to malnutrition in people living with HIV, good oral hygiene and care is needed in such individuals. Dental and oral diseases can render the individual unable to chew or swallow because pain and discomfort that can be caused by ulcers, bleeding gingiva and carious teeth. As a result an individual may find it difficult to maintain their health and have poor adherence to medication. Malnutrition, can then consequently affect how the body reacts to medication. In addition, any infection can stimulate the virus to grow, resulting in loss of viral suppression and higher viral loads. The oral cavity is often the first to show signs of immunosuppression with oral opportunistic infections such as severe gingivitis, necrotizing ulcerative gingivitis, candidiasis and hairy leukoplakia often visible in those with poor oral hygiene or those who present with side effects as a result of the ARV medication.

Methods

Inclusion/exclusion criteria

The five reviewed articles were selected based on the inclusion criteria of: Articles published in English, studies carried out from January 2005 to November 2019 (recent data of less than 15 years), oral epidemiological studies related to oral manifestations of HIV and articles involving studies on both children and adults were included.

The exclusion criteria to ensure uniformity of the studies were:

- Articles that were more than 15 years old were not considered.
- Individual case reports were not included.
- Articles that included other systemic diseases, such as Diabetes Mellitus and malignancies, which could adversely affect oral health, were excluded.

Study abstraction

An extensive literature search was conducted to collect the appropriate studies for the inclusion of this review. The electronic retrieval systems and databases that were used in the search for relevant articles were PubMed and Google Scholar. A total of 41,237 articles were found on these sites, of which only 5 were included intensively in this review. A further assessment of all references cited in the included articles was conducted, to ensure that those publications that were not initially identified with the search criteria could be included. Refer to the flow diagram in figure 1, for a summary of the systematic search results.

Data extraction

Data from all articles included in the review were extracted independently. Extracted data included authors, publication year, methodologies used to guide the implementation of the studies, outcomes, measures used in collection of data and the main findings.

Authors	Candidiasis	Ulcer	Angular cheilitis	Oral hairy leukoplakia	Kaposi sarcoma	Necrotizing gingivitis
Sharma, <i>et al.</i> 2015	37.7%	4.1%	-	10.1%	2%	7.6%
Kroidl, <i>et al.</i> 2005	7.2%	1.4%	-	3.6%	0.7%	1.4%
Ranganathan, <i>et al.</i> 2010	56.1%	4.24%	20.28%	1.41%	-	-
Adebola, <i>et al.</i> 2012	35.23%	12.38%	43.80%	-	-	-
Nabbanja, <i>et al.</i> 2013	50.54%	4.07%	10.32%	4.34%	3.26%	4.07

Table 1: The types and prevalence of dental and oral diseases in people living with HIV.

Results

According to the compiled results from all the articles, it is clear that HIV-oral related diseases are a common finding in those living with HIV. Based on review of the articles, oral candidiasis (OC) was the most common HIV-oral related disease finding.

In the five articles reviewed, the OC had a combined prevalence of 37.35%, with an associated high incidence of angular cheilitis

at 14.88% in both adults and children. Oral Kaposi Sarcoma was noted to be the least occurring oral manifestation at 0.01%.

In the study conducted by Kroidl, *et al.* [4] significant associations with a low CD-4 count was found for both OC and necrotizing gingivitis but no association to viral load.

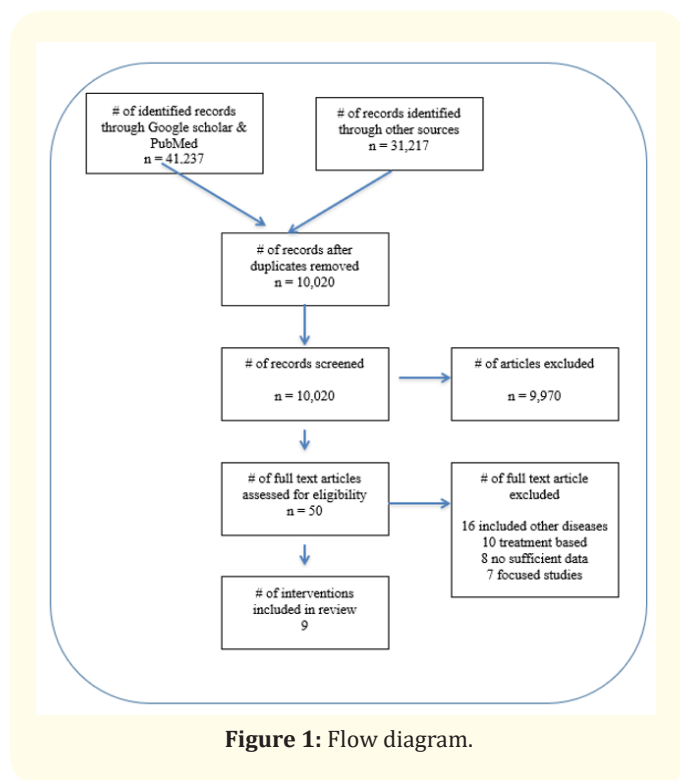


Figure 1: Flow diagram.

Discussion

According to the reviewed articles, oral candidiasis (OC) is the most common HIV-oral related disease that presents. In one of the studies, Aškinytė, *et al.* the presence of OC is strongly associated with a low CD4 count and had occurred in as many as 90% of patients before the introduction of HAART. Currently, OC still remains common in patients who are not aware of their status, those without treatment, those for whom treatment was started late and those in whom adherence is poor. Oral candidiasis normally presents in three forms: angular cheilitis, erythematous candidiasis, and pseudomembranous candidiasis.

The erythematous form, found on the dorsal surface of the tongue or on the soft and hard palate, is the most prevalent in HIV patients and presents with burning sensation while eating and drinking acidic beverages. Angular cheilitis, another OC form, was noted to be the second most occurring oral disease. Angular cheilitis is painful fissuring or erosion of the corners of the mouth and it can occur with or without erythematous candidiasis, explaining its high prevalence.

Based on the reviewed data collected by various studies, it is clear to see that evaluating oral health status of PLWH is very

important at every stage in the management of HIV disease. Oral candidiasis was found to be the most common oral pathology, in both children and adults, in all articles reviewed. All dental and oral lesions identified should be paid attention to, as most of these conditions are associated with immense pain and discomfort- this in return hinders the individuals ability to feed thus putting them at greater risk of malnutrition and eventually potential for opportunistic infections as they are not able to take medication and are generally unable to fend of infections. It is of utmost importance that health care providers be able to identify HIV-related oral manifestations, not only in the proper management of PLWH, but in also identifying HIV naïve patients. One major challenge of prevention of HIV, lies in HIV infected persons unaware of their status. A benefit of recognizing HIV-oral related diseases in such patients could thus assist with providing immediate health promotion and prevention possibilities. Hence, the importance of an integrated approach when dealing with PLWH should be sought [5-10].

Conclusion

The HIV/AIDS pandemic, and its associated dental and oral diseases, is still a major concern in many countries. And in many countries, evaluation of oral health status of people living with HIV is often omitted in the management of such individuals. Fully evaluating all HIV infected patients that present to a health facility is important at every stage of management of the disease. Thorough evaluation includes history taking, physical examination of all systems and appropriate investigations, when required. The necessity to identify HIV-related oral lesions is of the utmost importance for all health workers, as part of an integrated approach, as it can contribute effectively to the control of HIV/AIDS. Identification of HIV-oral related manifestations can assist with early diagnosis in HIV naïve patients; control the pandemic through interventions such as health education, patient care, infection control and surveillance.

Bibliography

1. CDC in Namibia. HIV/AIDS impact in Namibia. Retrieved from Global Health FactSheet, Namibian website (2017).
2. Kumar P and Clark M. Kumar and Clark’s Clinical Medicine (8th ed.) China: Saunders Elavier (2012).
3. Aškinytė D and Matulionytė Rimkevičius A. “Oral manifestations of HIV disease: a review”. *Stomatologija Baltic Dental and Maxillofacial Journal* 17 (2015): 21-28.
4. Kroid A, *et al.* “Prevalence of oral lesions and periodontal disease in HIV infected patients on antiretroviral therapy”. *European Journal of Medical Research* 10 (2005): 448-453.

5. Adebola AR, *et al.* "Oral manifestation of HIV/AIDS infections in paediatric Nigerian patients". *Niger Medical Journal* 53 (2012): 150-154.
6. Avert. Origin of HIV and AIDS (2019).
7. Greenspan D. "Oral manifestations of HIV Retrieved from HIV Insite Knowledge Base Chapter" (1998).
8. Nabbanja J., *et al.* "Orofacial manifestations in HIV positive children attending Mildmay Clinic in Uganda". *Odontology* 101 (2013): 116-122.
9. Ranganathan K., *et al.* "Orofacial and systemic manifestations in 212 paediatric HIV patients from Chennai, South India". *International Journal Paediatric Dentistry* 20 (2010): 276-282.
10. Sharma G., *et al.* "Oral manifestations of HIV/AIDS in Asia: Systematic review and future research guidelines". *Journal of Clinical and Experimental Dentistry* 7 (2015): e419-e427.

Assets from publication with us

- Prompt Acknowledgement after receiving the article
- Thorough Double blinded peer review
- Rapid Publication
- Issue of Publication Certificate
- High visibility of your Published work

Website: www.actascientific.com/

Submit Article: www.actascientific.com/submission.php

Email us: editor@actascientific.com

Contact us: +91 9182824667