



Comparison of Effectiveness between Acellular Dermal Matrix Allograft and Subepithelial Connective Tissue Graft with Coronally Advanced Flap in Recession Treatment: A Systematic Review

Vini Mehta^{1*}, Shreya Bagwe², D Gopalakrishnan³ and Ankita Mathur²

¹Department of Public Health Dentistry, Dr. D.Y. Patil Dental College and Hospital, Dr. D.Y. Patil Vidyapeeth, Pune, India

²Department of Periodontology, Dr. D.Y. Patil Dental College and Hospital, Dr. D.Y. Patil Vidyapeeth, Pune, India

³Professor and Dean, Department of Periodontology, Dr. D.Y. Patil Dental College and Hospital, Dr. D.Y. Patil Vidyapeeth, Pune, India

***Corresponding Author:** Vini Mehta, Department of Public Health Dentistry, Dr. D.Y. Patil Dental College and Hospital, Pune, Maharashtra, India.

Received: August 27, 2019; **Published:** September 05, 2019

DOI: 10.31080/ASDS.2019.03.0634

Abstract

Objective: The present review aims at comparing the effectiveness of Acellular Dermal Matrix Allograft (ADMA) with Subepithelial Connective Tissue Graft with Coronally Advanced Flap on the different clinical parameters.

Methods: Randomized controlled clinical trials with a follow up of at least 6 months published between 1st January 1980 to 31st July 2019 were identified from MEDLINE, the Cochrane Central Register of Controlled Trials, the National Institutes of Health Trials, Clinical Trials Registry India, Google Scholar and major journals. After a comprehensive search, the articles were independently screened for eligibility by two reviewers. All cross reference lists of the selected studies were screened for any additional papers. Studies who had localised or multiple Miller's Class I or II gingival recession were included.

Results: Sixteen articles out of 50 titles were found to meet the eligibility criteria. There was no significant difference between Subepithelial Connective Tissue Graft and ADMA with parameters such as recession height/depth, recession width, probing depth, clinical attachment level and root coverage gain. Although ADMA is expensive, it provides less surgical time, less postoperative pain, no addition of a second surgical site, has uniform thickness and can be used for multiple recession sites which is not possible with Subepithelial Connective Tissue Graft which requires a second surgical site and is technique sensitive.

Conclusions: ADMA can be used as an alternative for Subepithelial Connective Tissue Graft in Miller's Class I and Class II localized or multiple recession defects.

Keywords: Acellular Dermal Matrix Allograft; Gingival Recession; Connective Tissue Graft

Abbreviations

ADMA: Acellular Dermal Matrix Allograft; CAL: Clinical Attachment Level; PD: Probing Depth; CEJ: Cemento-Enamel Junction; RCT: Randomized Controlled Clinical Trials.

Introduction

Gingival recession is termed as oral exposure of root surface because of displacement of gingival margin apical to cemento-enamel junction (CEJ) [1]. The etiologies that contribute to gingival recession are toothbrush trauma, tooth malalignment, calculus,

gingival inflammation and orthodontic tooth movement [2,3]. Leading to deterioration of dental esthetics and development of cervical dentinal hypersensitivity [4].

Thus, to obtain a predictable and esthetic root coverage is a challenge and goal for the periodontist. The quest for attaining patient aesthetics lead to the attempt of surgical procedures like free gingival grafts, bilaminar techniques which consist of connective tissue graft with a pedicle graft, guided tissue regeneration, laterally positioned flap.

The subepithelial connective tissue graft developed by Langer and Langer [5] in 1985 described the use of subepithelial connective tissue graft as a donor site for root coverage which offered a combination of pedicle flap and free gingival graft.

Due to second surgical site being created on the palate for harvesting the connective tissue, the patient experiences discomfort due to post surgical pain from the donor area and also risk of bleeding [3]. So such candidates are not only subjected to recession but also may not be good candidate for obtaining proper thickness of connective tissue [6]. The above limitations led to discovery of substitutes like preserved sclera [7] for coverage of denuded roots and duramater [8] to obtain gain in width of attached gingiva and coverage of denuded roots.

Acellular Dermal Matrix allograft (ADMA) which has been introduced recently has been used as a substitute to autogenous connective tissue graft at gingival recession sites [9-12]. It is a freeze-dried, cell-free dermal matrix with a collagen and elastic fibre extracellular matrix, this allogenic material is human skin derived and further treated to remove antigenic targets of mediated immunity cells [3]. Since there is no need of a palatal donor site ADMA has an advantage over autogenous connective tissue graft.

Thus considering the available literature, the main aim of this systematic review was to assess effectiveness of ADMA compared to Subepithelial Connective Tissue Graft in Class I and Class II gingival recession using clinical outcome as variants for comparison.

Materials and Methods

Focused question

In patients with localized or multiple Miller's Class I or Class II gingival recession, which procedure gives the best possible results in terms of root coverage, clinical attachment level, probing pocket depth, width of keratinized gingiva, recession height and recession width?

Eligibility criteria

A literature search was performed for randomized controlled clinical trials (RCT) with a follow up of at least 6 months published between 1st January 1980 to 31st July 2019 assessing ADMA compared to Subepithelial Connective Tissue Graft in localized or multiple Class I and Class II gingival recession using clinical outcome such as root coverage, clinical attachment level, probing pocket depth, width of keratinized gingiva, recession height and recession width as variants for comparison. Studies published in English or those having detailed summary in English were

considered. Studies where systemic diseases, those who have undergone periodontal surgery in the past 12 months, patients with traumatic occlusion and teeth with root caries were excluded.

Search strategy

Two electronic databases were used to search for appropriate studies that would satisfy the study purpose: PubMed-MEDLINE, and the Cochrane Central Register of Controlled Trials using MeSH terms. Additional sources such as Google Scholar and major journals were explored. Ongoing trial registries such as The National Institutes of Health Trials and Clinical Trial Registry India were searched. Contact with authors was done for any unpublished studies.

Screening and selection

The papers were independently scanned by two reviewers (SB and DG), first by the title and abstract. If the search keywords were present in the title and/ or the abstract, the papers were selected for full-text reading. Papers without abstracts but with titles suggesting that they were related to the objectives of this review were also selected to screen the full text for eligibility. After selection, full-text papers were read in detail by two reviewers (SB and DG). Those papers that fulfilled all of the selection criteria were processed for data extraction. Two reviewers (SB and DG) hand searched the reference lists of all selected studies for additional relevant articles. Disagreements between the two reviewers were resolved by discussion. If a disagreement persisted, the judgment of a third reviewer (VM) was considered decisive.

Data extraction

From the collection of papers that met the inclusion criteria, data were extracted with respect to the effectiveness of ADMA with Subepithelial Connective Tissue Graft on root coverage [3], recession height [13], recession width [14], width of keratinized gingiva [3], clinical attachment level, probing pocket depth.

Results

Search and selection results

The PubMed-MEDLINE, Cochrane Central, and other sources identified 588 unique records which were screened by titles and abstracts (Figure 1). After full-text reading, 141 records were excluded. This exclusion resulted in 22 full-text articles. The remaining sixteen studies [10,14-24,27,28] that fulfilled the selection criteria were processed for data extraction. Additional hand searching of the reference lists of the selected studies yielded no additional records. An overview of the selected studies and their characteristics are presented in Table 1.

Author name	Location	Study design	Sample size	Setting	Condition	Intrvention	Comparison	Evaluation period	Confounders	Outcome	Results
Henderson RD et al 2001	Oklahoma city	RCT	10	Hospital	Miller's Class I and ClassII	Acellular dermal matrix graft+CAF	Subepithelial connective tissue graft+CAF	12 months	sites with no recession, Class III and Class IV	PD,CAL Keratinized tissue	Increase in keratinized tissue at primary recession sites
Novaes Jr. AB et al 2001	Sao Paulo	RCT	9 patients with 30 recessions	Hospital	Miller's Class I and ClassII	Acellular dermal matrix graft+CAF		6 months		PD, CAL,width of keratinized tissue	The advantage of ADMA is that a 2nd surgical site is avoided & the amount of material available is not limited, compared to a limited amount of connective tissue harvested from the palate, thus allowing the treatment of multiple defects.
Tal H et al 2002	Tel Aviv	RCT	7 patients with 14 teeth	Hospital	Miller's Class I and ClassII	Acellular dermal matrix allograft+CAF	Subepithelial connective tissue graft+CAF	12 months		PD, width of keratinized gingiva	Mean defect coverage & predictability were high & favorably compared with previous reports of connective tissue grafting.
Rahmani ME et al 2006	Mashad institut	RCT	14 patients with 20 gingival recessions	Hospital	Miller's Class I and ClassII	Acellular dermal matrix graft +CAF	Subepithelial connective tissue graft+CAF	6 months		PD, keratinized gingiva, recession width , CAL	ADMA and SCTG techniques could produce the same results when used for the successful treatment of gingival recessions. In addition the ADMA could be used as an adequate alternative treatment modality for conventional techniques.
Haghighati F et al 2006	qFaculty of Dentistry, Tehran University of Medical Science	RCT	9 patients with 32 recessions	Hospital	Miller's Class I and ClassII	Acellular dermal matrix allograft+CAF	Subepithelialconnective tissue graft +CAF	6 months		PD, Recession width, CAL	The use of ADMA yields similar results to that of connective tissue grafts with the advantage of avoiding a second surgery for the removal of palatal tissue at the donor site. Other advantages of ADMA are reduction in operative time & it does not require a specialist. However, the high cost of ADMA could be considered as disadvantage.
Tarun Kumar AB et al 2009	Davangere	RCT	9 patients with 18 defects	Hospital	Miller's Class I and ClassII	Acellular dermal matrix allograft+CAF		6 months		width of keratinized tissue, PD, CAL,root coverage	ADMA is equally effective to connective tissue graft in treatment of localized gingival recession. Second surgical site is avoided,patient morbidity due to palatal donor site can be avoided & availability of unlimited grafts for treating multiple recession defects
Mansouri SS et al 2010	Tehran university of Medical Sciences	RCT	5 patients with 9 bilateral defects	hospital	Miller's Class I and ClassII	Acellular dermal matrix allograft+CAF	SubepithelialConnective tissue graft +CAF	6 months		Recession height, recession width, keratinized gingiva,CAL,PD	Alloderm is able to yield acceptable results compared to SCTG in treating shallow to moderate gingival recessions, simplifying the surgery, eliminating the need for a second surgical site & permitting the one-stage treatment of an unlimited number of defects.
Jazi MN et al 2011	Tehran University	RCT	15	Hospital	Miller's Class I and ClassII	Acellular dermal matrix graft +CAF	Subepithelial connective tissue Graft+CAF	60 months		recession width , width of feratinized gingiva, root coverage	ADMA in 2nd surgical area is avoided & the amount of material available is not limited, compared to the limited amount of connective tissue harvested from the palate, thus allowing the treatment of multiple defects. The use of allograft contributed to a significant reduction in the patient morbidity and surgical risks. ADMA was similar to SCTG, which implies that in spite of its expense, it is a suitable material for root coverage.
Koudale SB 2012	Wardha	RCT	10	Hospital	Miller's Class I and ClassII	Acellular dermal matrix allograft+CAF	Subepithelial connective tissue graft+CAF	6 months		PD, CAL,width of keratinized tissue	ADMA for palatal donor material is eliminated,which reduces post operative morbidity .In addition it provides an unlimited supply of graft material thus permitting multiple site root coverage, that can be extended for a sextant, quadrant, or even a full mouth arch at one time.
Thomas LJ et al 2013	Alapakkam	RCT	10 patients with 20 recession sites	Hospital	Miller's Class I and ClassII	Acellular dermal matrix allograft+CAF	Subepithelial connective tissue graft +CAF	6 months		Recession height, recession width, keratinized gingiva,CAL,PD	There was no statistically significant difference in recession height and width, gain in CAL, and increase in the width of keratinized gingiva between the two groups on the 180th day. Both procedures showed clinically and statistically significant root coverage. The results indicate that coverage of denuded root with both subepithelial connective tissue autograft and ADMA are very predictable procedures, which were stable for 6 months postoperatively.
Aichelmann R et al 2001	Louisiana	RCT	22	Hospital	Miller's Class I and ClassII	Acellular dermal matrix allograft+CAF	Subepithelial connective tissue graft+CAF	6 months		recession width, recession height, root coverage, PD, CAL	Significant gains in root coverage, CAL, keratinized tissue were obtained using subepithelial placement of ADMA. Despite statistical differences, the test material performed similar to connective tissue graft.This implies that alternative donor tissue, acellular allogenic freeze dried drmal matrix may be a suitable substitute for autogenous connective tissue graft for root coverage in treatment of human gingival recession.
BT et al 2015	Kuala Lumpur	RCT, parallel design	6	Hospital	Miller's Class I and ClassII	Acellular dermal matrix graft +CAF	Subepithelial connective tissue graft+CAF	6 months		recession height, recession width, PD	It was concluded that ADMA & subepithelial connective tissue graft yield similar outcomes when used in treatment of gingival recession defects
Paolontino et al 2002	Italy	RCT		Hospital	Miller's Class I and ClassII	Acellular dermal matrix graft +CAF	Subepithelial connective tissue graft+CAF	12 months			When compared to connective tissue grafts, ADM produces a lower risk in keratinised tissue. Therefore, it should not represent the technique of choice when a maximum increase in keratinised tissue the goal of surgical procedure
Joly JC et al 2007	Brazil	RCT		Hospital	Miller's Class I and ClassII	Acellular demal matrix graft +CAF	Subepithelial connective tissue graft+CAF	6 months		PD, CAL	The coronally positioned flap associated with a connective tissue graft provided a more favorable outcome
Shori T et al 2012	Nagpur	RCT		Hospital	Miller's Class I and ClassII	Acellular dermal matrix allograft+CAF	Subepithelial connective tissue graft+CAF	6 months			The amount of root coverage in SCTG group was almost equivalent to ADMA, though SCTG showed slightly better result.

Table 1: Overview of the studies processed for data extraction.

Showing the comparison between Coronally advanced flap and Subepithelial Connective Tissue Graft and Coronally advanced flap with Acellular Dermal Matrix Allograft (ADMG)

*SCTG: Subepithelial Connective Tissue Graft, CAF: Coronally Advanced Flap, ADMA: Acellular Dermal Matrix Allograft

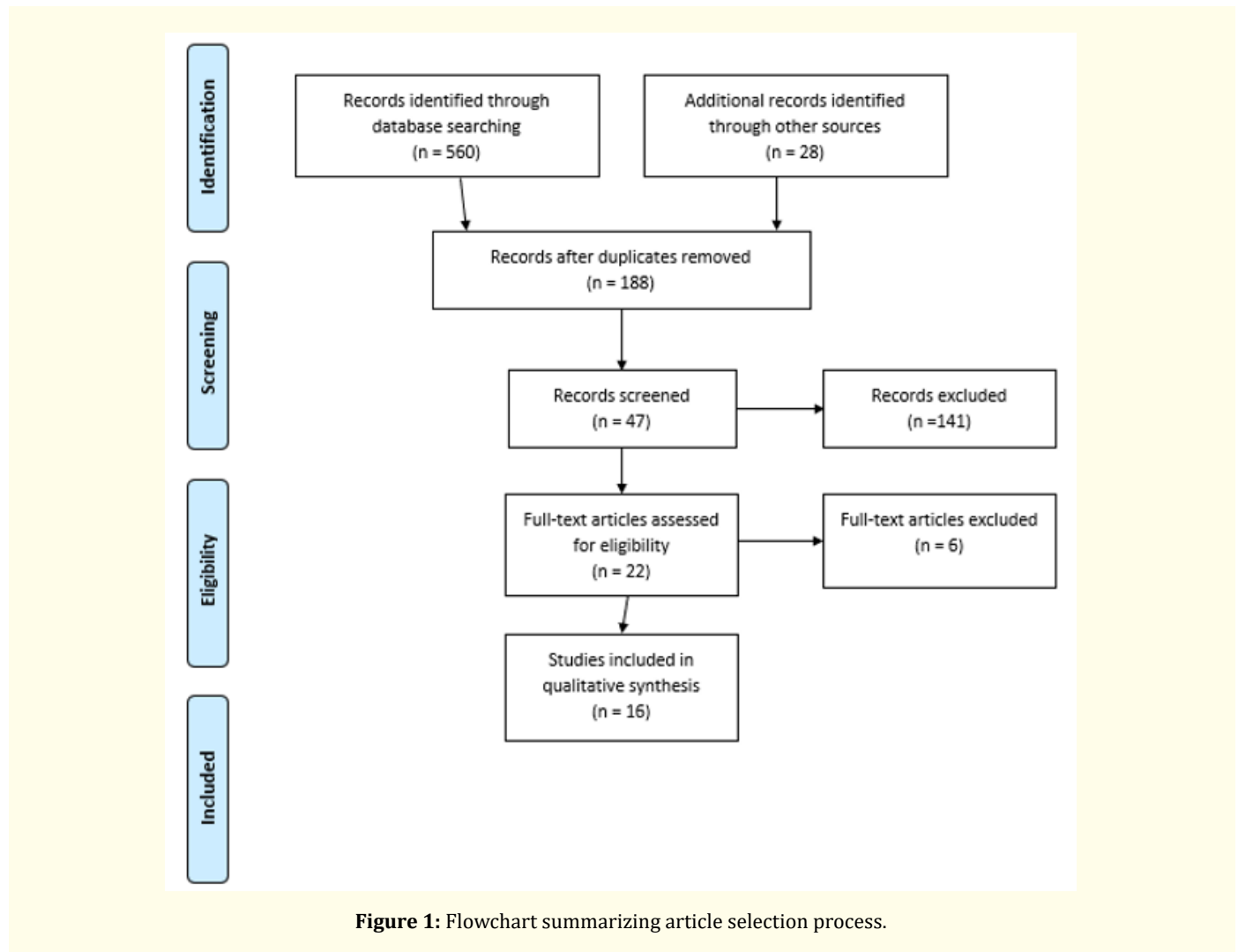


Figure 1: Flowchart summarizing article selection process.

Study characteristics

Eight RCTs followed split mouth design [14-16,20-24], six RCTs followed parallel design [10,17,23,24,27,28], one RCT followed both [19] and remaining one showed [18] block randomization. A total of 186 patients with 307 recession defects were included and all the randomized controlled trials were conducted in hospital setting. The included studies selected from the dental literature had Subepithelial Connective Tissue Graft plus Coronally Advanced Flap as control and Acellular Dermal Matrix Allograft as intervention with a minimum follow up period of 6 months till long term follow up which lasted for 60 months.

Outcome parameters

The recession height/recession depth, recession width, clinical attachment level, probing depth reduction were recorded in the following studies. [15-19,21-27]. However there was no statistical significance between the two groups with respect to recession

height/recession depth, recession width, clinical attachment level, probing depth reduction. 10 RCTs [15-17,20-23,26-28]. 3 studies [15,17,24] recorded statistically significant changes in increase in width of keratinised gingiva in subepithelial connective Tissue Graft group when compared with Acellular Dermal Matrix group. Although one study [22] showed increase in keratinised tissue in Acellular Dermal Matrix Group compared to Subepithelial Connective tissue group but it was not statistically significant. All studies showed root coverage gain. 5 studies [17,18,23,24,26] showed complete root coverage.

Discussion

During the past few years, the effectiveness of Periodontal Plastic surgery in treatment of localized or multiple recession defects have been recorded. Out of the several techniques being followed for treatment of gingival recession, two techniques namely, Subepithelial Connective Tissue Graft plus Coronally Advanced Flap

and Acellular dermal Matrix Allograft plus Coronally Advanced Flap have been studied in recent years for their effectiveness in treatment of gingival recession.

Hagighati F [18] reported that Acellular Dermal Matrix allograft caused reduction in operative time and does not require a skilled clinician. On the other hand, Tarunkumar AB [21], showed that Connective Tissue Graft is technically sensitive. Koudale SB., *et al.* [25] reported that Acellular Dermal Matrix Allograft has unlimited supply of graft material and could be used for multiple root coverage which could be extended for sextant, quadrant or full mouth arch at one time. However, Thomas., *et al.* [26] reported that Acellular dermal Matrix is expensive, yet it is a suitable material for root coverage. Paolantino M., *et al.* [17] reported that Connective Tissue Graft showed quicker healing. In a randomized clinical trial based on analysis of patient acceptance conducted by Goyal N., *et al.* [28], they showed ADMA better in terms of duration of surgical procedure and postoperative comfort. However, the high cost of acellular dermal matrix was reported by four patients in this study.

Limitation

Although, the major databases were used for the literature search, papers might have been missed because they might not be listed in these sources. The present review encompasses articles published in English language, which may have excluded potentially valuable evidence. There is a dearth of literature in histologic evaluation and comparison of healing. Most of the studies did not have a long term follow up and did not include all the parameters.

Implications in Future Research

Long term research needs to be carried out to evaluate Acellular Dermal Graft in shallow defects. Also there is a need to conduct studies on the mechanism of increase in width of keratinized gingiva and compare the creeping attachment when treated with Acellular Dermal Matrix Graft.

Conclusion

Although ADMA is expensive, it provides less surgical time, less postoperative pain, no addition of a second surgical site, has uniform thickness and can be used for multiple recession sites which is not possible with Subepithelial Connective Tissue Graft which requires a second surgical site and is technique sensitive. Thus it can be concluded that, Acellular Dermal Matrix Allograft can be used as an alternative for Subepithelial Connective Tissue Graft in Miller's Class I and Class II localized or multiple recession defects.

Conflict of Interest

None declared.

Bibliography

1. Wennstorm JL and Zucchelli G. "Increased gingival dimensions. A significant factor for successful outcome of root coverage procedures? A 2 year prospective clinical study". *Journal of Clinical Periodontology* 23 (1996): 770-777.
2. Gorman WJ. "Prevalence and etiology of gingival recession". *Journal of Periodontology* 38 (1967): 3163-3122.
3. Hall WB. "Pure Mucogingival versus Mucogingival - Osseous Problems". In: Binder P, managing editor. *Critical Decisions in Periodontology*. 4th edition. B C Decker Inc Ontario. (2008): 61.
4. Chambrone LA and Chambrone L. Subepithelial connective tissue grafts in the treatment of multiple recession defects". *Journal of Periodontology* 77 (2006): 909-916.
5. Langer B and Langer L. "Subepithelial Connective Tissue Graft Technique for Root Coverage". *Journal of Periodontology* 56 (1985): 715-720.
6. Muller HP and Eger T. "Masticatory mucosa and periodontal phenotype: A review". *International Journal of Periodontics Restorative Dentistry* 22 (2002): 172-183.
7. Klingsberg J. "Preserved sclera in periodontal surgery". *Journal of Periodontology* 43 (1972): 634-639.
8. Schoo WH and Coppes L. "Use of palatal mucosa and lypholized duramater to create attached gingiva". *Journal of Clinical Periodontology* 3 (1976): 166-172.
9. Harris RJ. "A comparative study of root coverage obtained with acellular dermal matrix versus a connective tissue graft: Results of 107 recession defects in 50 consecutively treated patients". *International Journal of Periodontics Restorative Dentistry* 20 (2000): 51-59.
10. Aichelmann-Reidy ME., *et al.* "Clinical evaluation of acellular allograft dermis for the treatment of gingival recession". *Journal of Periodontology* 72 (2001): 998-1005.
11. Tal H. "Subgingival acellular dermal matrix allograft for treatment of gingival recession". *Journal of Periodontology* 70 (1999): 1118-1124.

12. Miller PD. "Classification of Marginal Tissue Recession". *International Journal of Periodontics Restorative Dentistry* 5 (1985): 8-13.
13. Elgmati AAM., et al. "The use of Acellular Dermal Matrix Allograft in the Treatment of Gingival Recession". *Mansoura Journal of Dentistry* 1(3) (2014): 24-33.
14. Henderson RD., et al. "Predictable multiple site root coverage using an acellular dermal matrix allograft". *Journal of Periodontology* 72 (2001): 571-82.
15. Tal H., et al. "Root coverage of advanced gingival recession: A comparative study between acellular dermal matrix allograft and subepithelial Connective Tissue Grafts". *Journal of Periodontology* 73.12 (2002): 1405-1411.
16. Novaes AB. "Comparative 6 month Clinical study of a Subepithelial connective Tissue Graft for the Treatment of Gingival Recession". *Journal of Periodontology* 72 (2001): 1299-1307.
17. Paolantonio M., et al. "Subpedicle acellular dermal matrix graft and autogenous connective tissue graft in the treatment of gingival recessions: a comparative 1-year clinical study". *Journal of Periodontology* 73 (2002): 1299-307.
18. Haghghati F., et al. "Comparative Clinical Evaluation of Subepithelial Connective Tissue Graft and Acellular Dermal Matrix Allograft for the Treatment of Gingival Recession". *Journal of Dentistry of Tehran University of Medical Sciences* 3 (2006): 159-166.
19. Rahmani ME and Lades MA. Comparative clinical evaluation of acellular dermal matrix allograft and connective tissue graft for the treatment of gingival recession". *The Journal of Contemporary Dental Practice* 7 (2006): 63-70.
20. Joly JC., et al. "Root coverage in isolated gingival recessions using autograft versus allograft: a pilot study". *Journal of Periodontology* 78 (2007): 1017-1022.
21. Tarunkumar AB and Mehta SS. "Comparative Evaluation of Subepithelial Connective Tissue Graft (SCTG) and Acellular Dermal Matrix Allograft (ADMA) in the Treatment of Localized Gingival Recession- A Clinical Study". *Journal of the International Clinical Dental Research Organization* 2 (2009): 8-16.
22. Sadat Mansouri S., et al. "A comparative 6-month clinical study of acellular dermal matrix allograft and subepithelial connective tissue graft for root coverage". *Journal of Dentistry (Tehran)* 7 (2010): 156-164.
23. Moslemi N., et al. "Acellular dermal matrix allograft versus subepithelial connective tissue graft in treatment of gingival recessions: a 5-year randomized clinical study". *Journal of Clinical Periodontology* 38 (2011): 1122-1129.
24. Shori T., et al. "A comparative evaluation of the effectiveness of subpedicle acellular dermal matrix allograft with subepithelial connective tissue graft in the treatment of isolated marginal tissue recession: A clinical study". *Journal of Indian Society of Periodontology* 17 (2013): 78-81.
25. Koudale SB., et al. "A comparative clinical evaluation of acellular dermal matrix allograft and sub-epithelial connective tissue graft for the treatment of multiple gingival recessions". *Journal of Indian Society of Periodontology* 16 (2012): 411-416.
26. Thomas LJ., et al. "A comparative clinical study of the efficacy of subepithelial connective tissue graft and acellular dermal matrix graft in root coverage: 6-month follow-up observation". *Journal of Indian Society of Periodontology* 17 (2013): 478-483.
27. Taiyeb Ali TB., et al. "Efficacy of acellular dermal matrix and autogenous connective tissue grafts in the treatment of gingival recession defects among Asians". *Journal of Investigative and Clinical Dentistry* 6 (2015): 125-132.
28. Goyal N., et al. "Analysis of patient acceptance following treatment of Miller's class II gingival recession with acellular dermal matrix and connective tissue graft". *Journal of Indian Society of Periodontology* 18 (2014): 352-356.
29. Wei PC., et al. "Acellular dermal matrix allografts to achieve increased attached gingiva. A clinical study". *Journal of Periodontology* 71 (2000): 1297-1305.
30. Karring T., et al. "The role of gingival connective tissue in determining epithelial differentiation". *Journal of Periodontal Research* 10 (1974): 1-11.

Volume 3 Issue 10 October 2019

© All rights are reserved by Vini Mehta., et al.