



Four Rooted Mandibular First Molar with Four Root Canals: A Rare Case

Dakshita Joy Sinha^{1*} and Ashish Amit Sinha²

¹Associate Professor, Department of Conservative Dentistry and Endodontics, Kothiwal Dental College Research Centre and Hospital, Moradabad, India

²Associate Professor, Department of Pedodontics, Kothiwal Dental College Research Centre and Hospital, Moradabad, India

*Corresponding Author: Dakshita Joy Sinha, Associate Professor, Department of Conservative Dentistry and Endodontics, Kothiwal Dental College Research Centre and Hospital, Moradabad, India.

Received: May 31, 2017; Published: July 25, 2017

Abstract

Successful endodontic treatment largely depends on the thorough knowledge of the root and root canal morphology. An acknowledged characteristic of mandibular permanent molars are anatomical variations.

Negligence of the operator in recognizing the presence of anatomic irregularities in teeth like accessory or aberrant roots and root canals may often lead to untreated root canals that may further result in failure of the root canal treatment. This paper describes the anatomical variation of four roots in a mandibular permanent first molar diagnosed using multiple angulated preoperative radiographs and its successful nonsurgical endodontic management. This finding and the morphology of the root was confirmed with computed tomography (CT). This report attempts at making the dental fraternity aware of this morpho-anatomical variation, its prevalence and endodontic management thereby rendering more efficient endodontic treatment.

Keywords: Computed Tomography; Endodontic Management; Four Rooted Mandibular First Molar; Radix Entomolaris; Radix Paramolaris

Introduction

Higher success rates have been associated with an awareness and understanding of the most common root and root canal configuration and also its anatomic deviations that allow a more effective root canal disinfection. An incompletely removed pulp tissue and micro-organisms from the root canal system are most important reasons for root canal failure in molars [1].

The permanent mandibular first molar also known as the “6-year molar,” is the largest tooth in volume and most complex in root and canal anatomy. Probably it is the most operated upon and least understood posterior tooth [2]. The mandibular first molar is typically a two-rooted tooth with a mesial and a distal root. However, the Non-Asian populations have an incidence of two roots in 96.9% cases, while in Asian populations this is about 75.9% [3,4]. An additional third root, located distolingually in mandibular molars denominated as radix entomolaris was first mentioned in the literature by Carabelli [5]. Whereas radix paramolaris is an additional root at the mesio-buccal side. Carlsen and Alexandersen have described the identification and external morphology of these root complexes, containing a lingual or buccal supernumerary root [6,7] but mention of a four-rooted mandibular molar sometimes encountered in the clinical practice in the literature is rare. Three-rooted mandibular first molars occur in less than 5% of the Indian population [8]. The incidence of four rooted molars are reported to be less than 1% [9]. The endodontic treatment of a mandibular molar

with aberrant canal configuration can be diagnostically and clinically challenging.

The purpose of the present paper is to report the successful nonsurgical endodontic management of a four-rooted permanent mandibular first molar with each root containing its own independent root canal.

Case Report

A 45-year-old female patient reported to the outpatient department of Conservative Dentistry and Endodontics, Kothiwal Dental College and Research Centre, Moradabad, Uttar Pradesh, India with the chief complaint of pain in the lower left back region of the jaw for 10 days. Pain was intermittent and occurred only on mastication. Family and medical health history were not relevant. On clinical examination, a grossly decayed 35 and crowned 36 were observed. Vitality tests elicited no response with respect to 35. On radiographic examination, 35 and mesial root of 36 revealed periapical radiolucencies.

Radiolucency was involving pulp with respect to 35. Also, the radiographic apical contour of the tooth suggested that there might be two distal and two mesial roots (Figure 1). From the clinical and radiographic findings, a diagnosis of pulpal necrosis with symptomatic apical periodontitis was made and endodontic treatment was initiated for both the teeth.

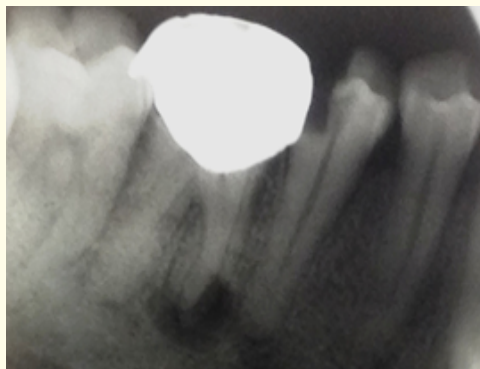


Figure 1: Preoperative Intraoral Periapical Radiograph Wrt 35,36 Revealing Radiographic Apical Contour of the Tooth Suggested that there might be Two Distal and Two Mesial Roots.



Figure 2: Clinical Photograph showing Four Orifices for 36 and Two for 35.

On the first visit, the crown on 36 was removed with a crown remover (GDC automatic crown remover). Rubber dam was applied and endodontic treatment initiated. Endodontic access cavities were made for 35 and 36. Following endodontic access cavity preparation, two mesial and one buccally placed distal canals were identified for 36. Upon visual inspection of the floor of the pulp chamber using a dental operating microscope (Global, India), a dark line was observed extending from the distal canal orifice towards the distolingual corner. At this corner, the overlying dentin was removed and a second distal canal orifice was detected with the aid of DG-16 explorer (Dentsply Maillefer, Ballaigues). The conventional access was modified to improve access to the additional canals. Also, two separate orifices were identified for the premolar namely, buccal and lingual (Figure 2). Root canals were negotiated with 15 size K-file (Mani Inc, Tokyo, Japan) and working length was determined for four canals in 36 and two canals in 35 using electronic apex locator (Root ZX, J Morita company, Tokyo, Japan). Working length was confirmed using intraoral periapical radiograph taken in mesial angulation as per same side lingual and opposite side buccal (SLOB) rule (Figure 3).

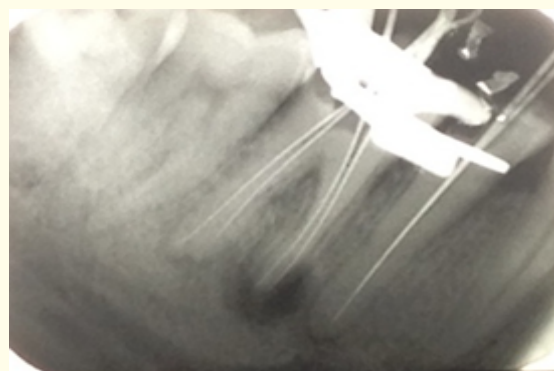
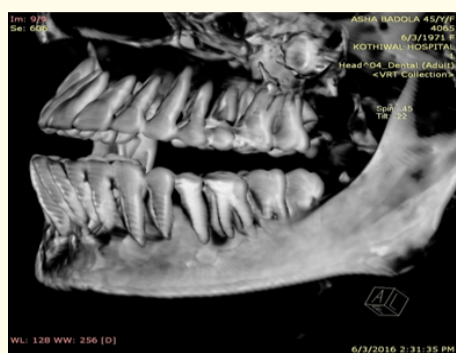
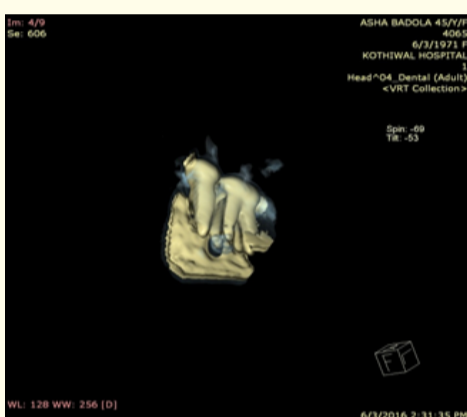
Figure 3: Working Length Radiograph for 35,36.

The canals were cleaned and shaped with hand K-files and nickel titanium rotary Pro Taper files (Dentsply Maillefer, Switzerland). The canals were sequentially irrigated using 5.25% Sodium hypochlorite and 17% EDTA during the cleaning and shaping procedure. Calcium hydroxide intracanal medicament was placed and cavities were sealed with IRM (Caulk/Dentsply Milford, USA). Patient was recalled after seven days.

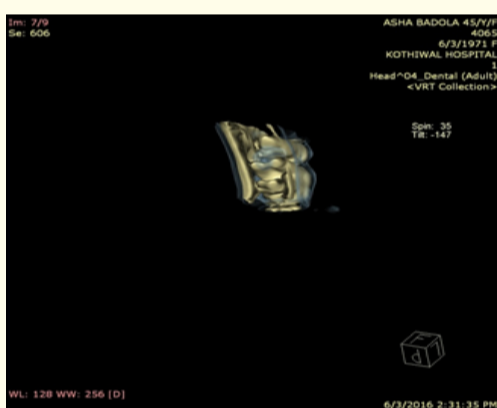
Also, it was decided to go in for the Computed Tomographic scan (CT Face 3-D; Siemens Germany 16 slices multidetector; Somatom Scope) of the patient to confirm the presence of four roots and canals and for academic purpose (Figure 4a,4b and 4c).



(a)



(b)



(c)

Figure 4a,4b and 4c: VRT Images using CT Scan of Left Mandibular First Molar showing Distinctive Separate Apices and Three-Dimensional Reconstruction of Tooth after Removal of Bone.

In the second visit, the canals were thoroughly dried and obturation was done using F2 Pro Taper Gutta-percha and AH Plus sealer (Dentsply, Maillefer, Switzerland). The post-endodontic permanent restoration was completed with amalgam (DPI Alloy Fine grain silver tin dental amalgam alloy, Deep dent products, Delhi, India) (Figure 5). The patient was found to be asymptomatic on follow up after 7 days and was advised to get the teeth crowned.

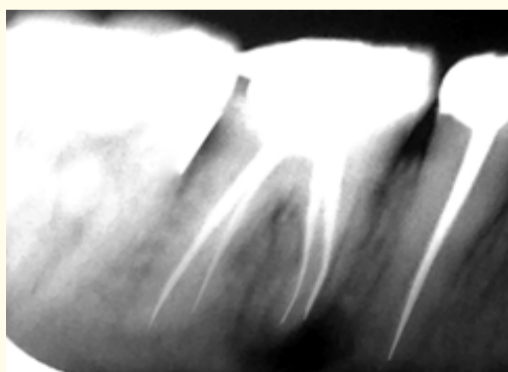


Figure 5: Post Obturation Radiograph with Post Obturation Restorations Wrt 35,36.

Discussion

A number of anatomical variations have been described in the mandibular first molar. Few case reports have previously described the presence of four rooted mandibular first molar [10-13]. However, two had reported three distal and one mesial root. The present report describes a four-rooted mandibular first molar with two mesial and two distal roots in which each of the four roots have an independent root canal; a rare case of radix paramolaris and radix entomolaris in the same tooth.

Also, a different pattern was noted from reports previously reported. Jojo Kottor, et al. had stated that the angle formed in four rooted mandibular molars between the DRFLs joining both the mesial and distal orifices is more acute unlike mandibular first molars with two roots and each root having two distinct canals (for instance, mesiobuccal and mesiolingual canals in the mesial root), where the angle formed between the developmental root fusion lines (DRFLs) joining these canal orifices is more obtuse [12]. But in the case reported the authors observed that in spite of four rooted mandibular molar the angle formed between the developmental root fusion lines (DRFLs) joining these canal orifices was almost 90 degrees or more.

Radiography plays an important role in the management of endodontic problems. The amount of information gained from conventional radiographs and digitally captured periapical radiographs is limited by the fact that the three-dimensional anatomy of the area being radiographed is compressed into a two-dimensional image [14] which results in superimposition of structures which have limited value in cases with complex root canal morphology. In the case reported here, a mesially angulated periapical radiograph of left mandibular permanent first molar revealed double periodontal ligament spaces in both mesial and distal roots suggesting presence of four roots. Newer diagnostic methods such as computerized axial tomography (CT) scanning greatly facilitate access to the internal root canal morphology and CT aids in 3D reconstruction of the root and canal morphology in a non-invasive manner. Multiple slices of tooth roots and their root canal systems can be viewed by the operator [15]. A major concern with the use of a CT scan is its high radiation dosage. But with Somatom Scope which was used in this case excellent image details are produced at low radiation doses.

With the aid of CT, it was seen that the left first mandibular molar had four roots and canals. This is the first case report till date to have reported the complete case along with the clinical photograph and CT images. The authors also did a four-rooted mandibular first premolar with four separate canals but did not take CT to confirm the morphology [16]. In this case report it was proved in a retained tooth.

Conclusion

Failure to locate and adequately debride extra canals may lead to unsuccessful endodontic treatment and unfavourable prognosis. An astute clinician should be aware of the root and canal morphology variations and should be able to use modern diagnostic aids if need be in order to render a successful endodontic outcome.

Acknowledgement

I would like to thank Mrs Asha Badola for being such a cooperative patient and allowing me to use her case for this paper. I would also like to acknowledge Mr Sanjay Sinha; Administrative officer for his valuable support, Mr Mukesh Kumar; CT Technician (MSc Radio Imaging and Technology) and dental attendant Mr Babloo, Kothiwal Dental College and Research Centre, Moradabad, U.P-244001, India.

Conflicts of Interest

The authors deny any conflicts of interest.

Bibliography

1. Cohen AS and Brown DC. "Orfacial dental pain emergencies: Endodontic diagnoses and management". In: Cohen S, Burns RC, editors. *Pathways of the Pulp*. 8th edition. Boston: Mosby; (2000): 31-75.
2. RC Burns and EJ Herbranson. "Tooth morphology and access cavity preparation". in *Pathways of the Pulp*, S. Cohen and R. C. Burns, Eds., Mosby, St Louis, Mo, USA, 8th edition, (2002): 173-229.
3. Ingle JL, et al. "Ingle's Endodontics". 6th edition, Hamilton: BC Decker Inc, (2008).
4. Singh S., et al. "Endodontic Management of Four Rooted Mandibular First Molar: A Rare Case". *Journal of Dental Herald* 2 (2015): 3-4.
5. Carabelli G. "Systematic handbook of dentistry". Vol. 114, 2nd edition. Vienna: Brewing Muller and Seidel; 1844.
6. Carlsen O and Alexandersen V. "Radix paramolaris in permanent mandibular molars: Identification and morphology". *Scandinavian Journal of Dental Research* 99 (1991): 189-195.
7. Carlsen O and Alexandersen V. "Radix entomolaris: Identification and morphology". *Scandinavian Journal of Dental Research* 98.5 (1990): 363-373.
8. Ferraz JA and Pe'cora JD. "Three rooted mandibular molars in patients of Mongolian, Caucasian and Negro origin". *Brazilian Dental Journal* 3.2 (1992): 113-117.
9. Cleghorn BM., et al. "Morphology of teeth and their root canal systems". In: Ingle J, Bakland L, editors. *Ingle's Endodontics*. Hamilton: BC Decker Inc; (2008): 151-220.
10. S Friedman., et al. "Five root canals in a mandibular first molar". *Endodontics and Dental Traumatology* 2.5 (1986): 226-228.
11. SJ Lee., et al. "Three-dimensional visualization of a mandibular first molar with three distal roots using computer-aided rapid prototyping". *Oral Surgery, Oral Medicine, Oral Pathology, Oral Radiology and Endodontology* 101.5 (2006): 668-674.
12. Kottoor J., et al. "Four-Rooted Mandibular First Molar with an Unusual Developmental Root Fusion Line: A Case Report". *Case Reports in Dentistry* (2012): 1-4.
13. Koppolu M., et al. "Diagnosis and management of bilateral four rooted mandibular first molars". *Journal of Cranio-Maxillary Diseases* 3 (2014): 172-175.
14. Patel S., et al. "New dimensions in endodontic imaging: Part 1. Conventional and alternative radiographic systems". *International Endodontic Journal* 42.6 (2009): 447-462.
15. Tachibana H and Matsumoto K. "Applicability of X-ray computerized tomography in endodontics". *Endodontics and Dental Traumatology* 6.1 (1990): 16-20.
16. Vaghela DJ and Sinha AA. "Endodontic management of four rooted mandibular first premolar". *Journal of Conservative Dentistry* 16.1 (2013): 87-89.

Volume 1 Issue 2 July 2017

© All rights are reserved by Dakshita Joy Sinha and Ashish Amit Sinha.