

## Intracerebellar Malignant Nerve Sheath Tumor Not Related to Cranial Nerve

**Andrea Ortiz-Ordoñez<sup>1\*</sup>, Jaime Jara-Lalama<sup>1</sup> and Laura Bottani<sup>1,2</sup>**<sup>1</sup>Universidad San Francisco de Quito USFQ, Colegio Ciencias de la Salud, Calle Diego de Robles s/n y Pampite, Quito, Ecuador<sup>2</sup>Chairman of Neurosurgery Department, Hospital Eugenio Espejo, Quito-Ecuador**\*Corresponding Author:** Andrea Ortiz-Ordoñez, Neurosurgery Resident, Universidad San Francisco de Quito USFQ, Colegio Ciencias de la Salud, Calle Diego de Robles s/n y Pampite, Quito, Ecuador.**Received:** April 30, 2020**Published:** May 22, 2020© All rights are reserved by **Andrea Ortiz-Ordoñez, et al.****Abstract****Introduction:** Intracranial nerve sheath tumors not arising from cranial nerves are extremely rare, even more, when malignant degeneration.**Case Report:** Female adult presenting cerebellar syndrome and headache. Imaging showed an intracerebellar tumor and surgery was performed. Histopathology and immunohistochemistry were compatible with intracerebellar Triton tumor.**Discussion:** Twenty-five malignant intracerebral nerve sheath tumors have been reported in the literature. The presented case is not associated to neurofibromatosis; it is the fourth reported intracerebellar and the first showing rhabdomyoblastic differentiation in this location.**Conclusion:** Further studies are required to establish the cell origin and the best management for this entity.**Keywords:** Schwann Cell; Schwannoma; Malignant Intracerebral Nerve Sheath Tumor (MINST); Intracerebellar Malignant Nerve Sheath Tumor (ICMNST); Triton Tumor; Cerebellar Neoplasms**Abbreviations**

MINST: Malignant Intracerebral Nerve Sheath Tumor; ICMNST: Malignant Nerve Sheath Tumor; RT: Radiotherapy; H&amp;E: Hematoxylin and Eosin; GFAP: Glial Fibrillary Acid Protein; CK: Cytokeratin; EMA: Epithelial Membrane Antigen; HMB: Human Melanoma Black; GTR: Gross Total Resection

**Introduction**

Benign nerve sheath tumors (a.k.a. schwannomas) are usually associated with neurofibromatosis [1-3,7,8,12,13,17,19]. Its occurrence within the neuroaxis is uncommon (approximately 8% of all primary brain tumors) [7,8,12-15,22,25] and even rarer within brain or cerebellar parenchyma [2-4,7-10,15,16,20]. Intraparenchymal schwannomas not associated with cranial nerves represent 0.6% - 2% of all central and peripheral nerve schwannomas [2,4,8,10,12,15] and can occur at any age without gender predilection [2,19]. Some variants present cystic degeneration associated with intratumoral hemorrhage, which occurs especially with the most undifferentiated forms and with the highest cellular atypia with evidence of edema and peritumoral gliosis [1,5].

Schwannomas are not known to undergo malignant degeneration and hence, it is preferable to label it MINST (malignant intracerebral nerve sheath tumors) [1,16,19] and when rhabdomyoblastic differentiation is found, it is called Triton tumor which was described in 1932 by Masson [1,4,16].

It could mimic a malignant glioma on radiology and complete excision followed by radiation and chemotherapy seems to be the most appropriate treatment, but the prognosis is still poor [19].

**Case Report**

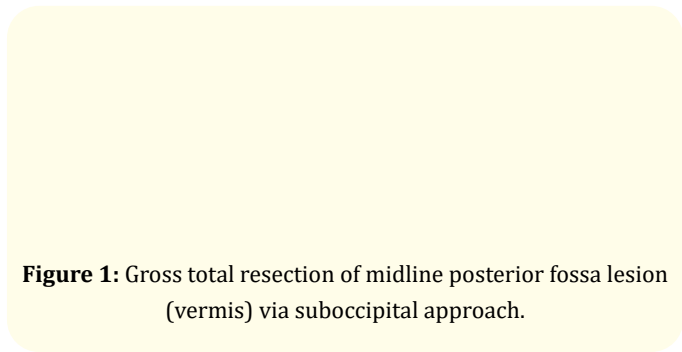
A 49-year-old woman with past medical history of breast cancer surgery 17 years ago (not known histopathology). The patient did not have any clinical evidence of neurofibromatosis or history of brain mass or prior radiation therapy. The patient presented to the emergency department complaining of headache and cerebellar syndrome (nystagmus, ataxia, dysmetria). Contrast-enhanced T1-weighted image revealed intraparenchymal posterior fossa tumor with heterogenous enhancing in vermis. Extensive perilesional edema was compressing the fourth ventricle and, hypointense in-

tralesional areas were described. At surgery, the tumor was firm with poorly defined edges, moderate vascularization, and a yellowish discoloration (Figure 1).

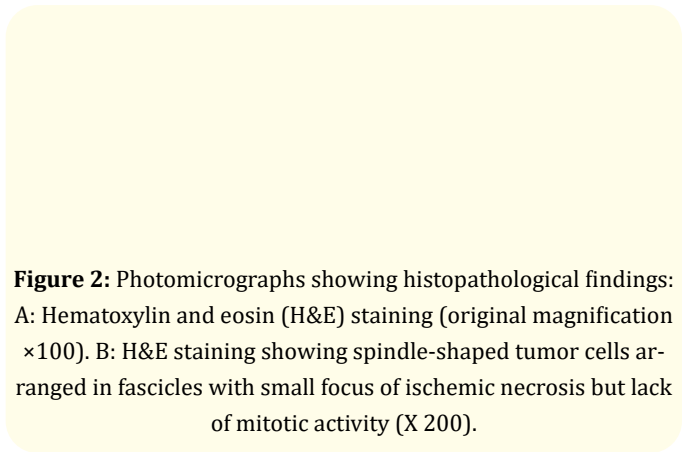
The initial histopathological study (Figure 2) reported fusocellular cells with elongated, pleomorphic nuclei arranged in a fence-like pattern (palisade) with hypocellular areas and myxoid degeneration. No mitotic activity was identified but there was a small focus of ischemic necrosis and cerebellum with preserved architecture.

The patient was discharged with good conditions, improvement in ataxia, and persistence of slight dysmetria. No chemo or radiotherapy were administered. After 4 months of follow up, she presented tumor recurrence (Figure 3) and a second surgery was performed.

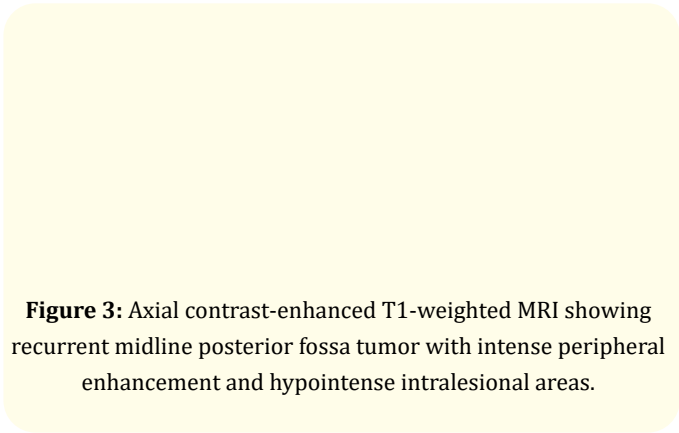
A new histopathological study (Figure 4) reported a malignant nerve sheath tumor with rhabdomyoblastic differentiation (Triton tumor). 16m/10c mitotic rate (40x) without lymphovascular invasion. Immunohistochemistry (Table 1) revealed immunopositivity for vimentin, confirming the mesenchymal differentiation and tumor cells showed patchy nuclear and cytoplasmic immunostaining for S-100, confirming the neural differentiation. The patient died at 6 months of follow up.



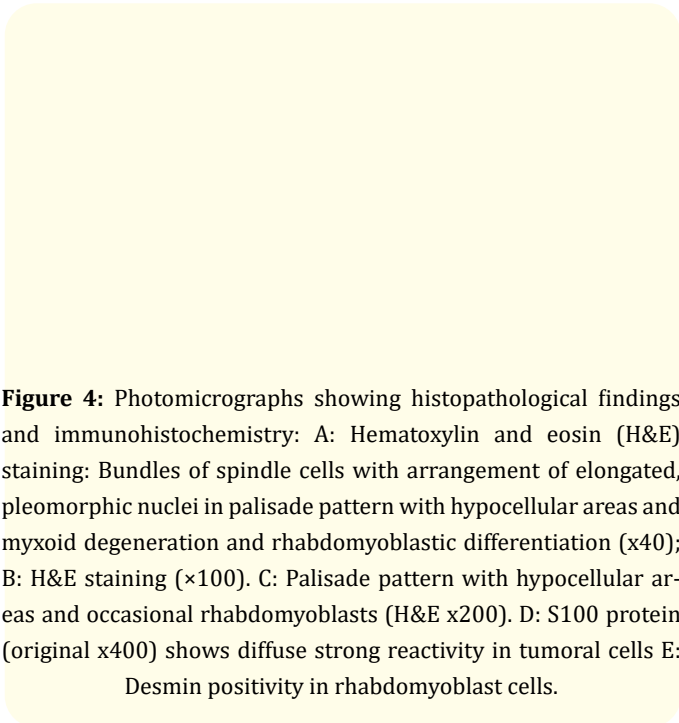
**Figure 1:** Gross total resection of midline posterior fossa lesion (vermis) via suboccipital approach.



**Figure 2:** Photomicrographs showing histopathological findings: A: Hematoxylin and eosin (H&E) staining (original magnification x100). B: H&E staining showing spindle-shaped tumor cells arranged in fascicles with small focus of ischemic necrosis but lack of mitotic activity (X 200).



**Figure 3:** Axial contrast-enhanced T1-weighted MRI showing recurrent midline posterior fossa tumor with intense peripheral enhancement and hypointense intralesional areas.



**Figure 4:** Photomicrographs showing histopathological findings and immunohistochemistry: A: Hematoxylin and eosin (H&E) staining: Bundles of spindle cells with arrangement of elongated, pleomorphic nuclei in palisade pattern with hypocellular areas and myxoid degeneration and rhabdomyoblastic differentiation (x40); B: H&E staining (x100). C: Palisade pattern with hypocellular areas and occasional rhabdomyoblasts (H&E x200). D: S100 protein (original x400) shows diffuse strong reactivity in tumoral cells E: Desmin positivity in rhabdomyoblast cells.

Marker	Result
GFAP	Positive
S100	Positive
CK	Negative
Actin	Negative
Desmin	Positive
CD34	Negative
EMA	Negative
HMB 45	Negative
Vimentin	Positive
Ki 67	15%

**Table 1:** Immunohistochemistry study.

**Discussion**

Intraparenchymal location of benign nerve sheath tumor was first described by David in 1965, then Gibson (1966), New (1972), and Ghatak (1975) reported new cases [3,7,9,12]. Seventy cases were reported up to 2011 [2] and 84 cases till 2018 [15]. Cerebellar (hemispheric and vermian) location has occasionally been described [2,15].

The term malignant intracerebral nerve sheath tumor (MINST) is preferred rather than malignant schwannoma because schwannomas usually do not have a bent towards malignancy [17,20,23]. Fifteen MINST cases were documented by Shweikh, *et al.* in 2013 and twenty-five cases, mostly supratentorial were reported within the literature by 2016 [23]. A variant with rhabdomyoblastic differentiation, referred to as malignant triton tumor, has been reported as well [16,17,23]; none infratentorial [17].

Singh, *et al.* [11] first described a case of malignant schwannoma of the right cerebellum in a 61-year-old female with raised intracranial pressure (ICP) and ataxia. The patient underwent tumor excision but died after 18 months with a tumor recurrence. Maiuri, *et al.* [4] reported a 29-year-old female, with a vermian lesion; survival after surgery was 8 months. Joshi, *et al.* [10] presented the primary case in children, a female patient with signs of raised ICP and ataxia as well; Joshi is the first to coin the term intracerebellar malignant nerve sheath tumor (ICMNST) to label the cerebellar location of such tumors [10]. This reported case corresponds to the fourth ICMNST documented in the literature [10,16,23], and the first with rhabdomyoblastic differentiation (Triton tumor) in this setting [17,23] (Table 2).

In addition to neurofibromatosis [17,19,20], other factors could predispose to MINST or ICMNST including a history of ionizing radiation exposure [2,8,17,19]; however, none was present in the

Author [reference]	Year	Age (years), sex	Tumor location	Surgery	RT	Recurrence (months)	Follow-up (months)
Singh, <i>et al.</i> [11]	1963	61, F	Right cerebellar	GTR	RT	8	18, dead
Maiuri, <i>et al.</i> [4]	2004	29, F	Vermis	GTR	-	8	8, dead
Joshi, <i>et al.</i> [10]	2014	8, F	Right cerebellar	GTR	RT	n/r	12, alive*
Ortiz-Ordonez, <i>et al.</i>	Current	44, F	Vermis	GTR	-	4	6, dead

**Table 2:** Literature review of intracerebellar malignant nerve sheath tumors ICMNST: location, time to recurrence and follow-up.

GTR: Gross Total Resection; RT: Radiotherapy; n/r: Not Reported.

\*: Patient was alive by the year of publication.

current case. Most MINST/ICMNST cases are sporadic and have afflicted patients of all ages [2,19,20].

Radiologically ICMNST should be differentiated from other cerebellar lesions like medulloblastoma, pilocytic astrocytoma, and hemangioblastoma in children [10,19] and particularly from gliomas or metastasis in adults [18-20]. Not surprisingly, the diagnosis of those tumors could also be difficult, and the unknown cellular origin complicates it more. Treatment nearly always involves surgery, but a definitive diagnosis requires histopathological examination, and immunohistochemical markers [4,11,17,19,20,23] like s-100 protein and vimentin staining [1,12,13,20]; glial fibrillary acidic protein can be positive [13].

Schwann cells are not ordinarily present in the cerebral or cerebellar parenchyma and it is difficult to elucidate its intracranial origin when cranial nerve association is not found. Schwann cells are present in perivascular nerve plexuses (adrenergic fibers supplying cerebral arterioles and in the subarachnoid space of great arteries) [2,6-9]. Different hypotheses have been proposed [12-

14]: the transformation of mesenchymal pial cells into Schwann cells [2,7-9], origin from ectopic nerve fibers or neural crest cells that have migrated incorrectly during nervous system development (theory of distorted embryogenesis stated by Nelson and Kennels in 1970 and Redekop, *et al.* in 1990) [2,7,9,11], or origin in multipotential mesenchymal cells (Feigin and Ogara in 1971); however, the existence of these cells deep in the parenchyma is uncertain [4,8,11,25]. Prakash, *et al.* [27] stated that myelinated fibers with Schwann cells may be found within the brain parenchyma as a hamartomatous malformation [10,11].

Malignant nerve sheath tumors with rhabdomyoblastic differentiation are called Triton tumors. They represent less than 5% of malignant neoplasms of peripheral nerve sheaths. Histological finding of differentiated skeletal muscle cells is typical (desmine, myoglobin, MyoD1, myogenin positive). According to some series, these tumors have a darker prognosis (5-year survival rate of 14%). The local recurrence rate is around 50% (median of 6 months). Triton tumor immunohistochemistry is characterized by muscle markers and S100 protein positivity [20,23].

Complete surgical removal of the ICMNST could be the foremost effective known treatment [10,20]. The role of adjuvant radiotherapy and chemotherapy in ICMNST is yet to be fully elucidated; however, radiotherapy may increase the survival rate additionally to gross total resection with healthy margins. [10,20,23]. While most Nerve Sheath Tumors exhibit an uneventful postoperative recovery, long-term outcomes are variable [19,21]. Three of four cases reported as ICMNST had poor overall survival (less than 2 years) and the worst scenario happened during this current case as rhabdomyoblastic differentiation was found (Table 2). Even with multimodality and interdisciplinary management of ICMNST patients, they show recurrences and fatal results [18,19,21].

### Conclusion

Further studies might help to elucidate the histogenesis of intracerebral and cerebellar nerve sheath tumors. Most reported cases have presented in young patients; henceforth, a developmental origin has been proposed. Postoperative radiotherapy might help in preventing recurrences and increasing the disease-free interval in MINST, but no survival rate improvement was seen in ICMNST.

### Acknowledgements

We thank Eugenio Espejo Hospital Pathology Department for assistance with description of histological microphotographs that greatly improved the case report

### Conflict of Interest

The authors declare that there is no conflict of interests regarding the publication of this paper.

### Bibliography

- Rinaldi M., et al. "Schwannomas intracranios: Nuestra experiencia (2000-2009)". *Revista Argentina De Neurocirugía* 23.3 (2009): 125.
- Umredkar A., et al. "Posterior fossa vermian cystic schwannoma mimicking as pilocytic astrocytoma: A case report and literature review". *Neurology India* 59.5 (2011) 756-760.
- Scott W., et al. "Intracerebral schwannomas: a rare disease with varying natural history Report of 3 cases". *Journal of Neurosurgery Pediatrics* 12 (2013): 6-12.
- Maiuri F., et al. "Malignant Intracerebellar Schwannoma". *Journal of Neuro-Oncology* 66 (2004): 191-195.
- Zagardo MT., et al. "Radiologic and pathologic findings of intracerebral schwannoma". *American Journal of Neuroradiology* 19.7 (1998): 1290-1293.
- Bollati A., et al. "Spinal intradural schwannoma without attachment to a nerve root". *Journal of Neurosurgery* 57.5 (1982): 701-702.
- Tran-Dinh HD., et al. "Cystic Cerebellar Schwannoma: Case Report". *Neurosurgery* 29.2 (1991) 296-300.
- Sharma MC., et al. "Intracranial intraparenchymal schwannomas: a series of eight cases". *Journal of Neurology, Neurosurgery, and Psychiatry* 60.2 (1996): 200-203.
- Abdulrahman Abdullah Al Batly., et al. "An atypical case of intracerebral schwannoma". *Pan African Medical Journal* 18 (2014): 342.
- Joshi C., et al. "Intracerebellar malignant nerve sheath tumor in a child: case report and review of literature". *Child's Nervous System* 31.5 (2015): 785-788.
- Singh RV., et al. "Malignant schwannoma of the cerebellum: Case Report". *Surgical Neurology* 39.2 9 (1993): 128-132.
- Sun I., et al. "Intracerebral Schwannoma: A Case Report". *Journal of Neurological Sciences* 32.2 (2015): 436-441.
- Al Anazi A., et al. "Intracerebral Schwannoma: A Case Report". *Neurosurgery Quarterly* 25.3 (2015): 385-387.
- Srinivas R., et al. "Intracerebral Schwannoma in a 16-Year-Old Girl: A Case Report and Review of the Literature. Hindawi Publishing Corporation". *Case Reports in Neurological Medicine* 171494 (2013): 3.
- Gao Yufei., et al. "Intracerebral schwannoma: A case report and literature review". *Oncology Letters* 16.2 (2018): 2501-2510.
- Shweikeh Faris., et al. "Malignant Intracerebral Nerve Sheath Tumors: A Case Report with Review of the Literature". *Corporation Case Reports in Surgery* (2013): 384076.
- Patankar Amey Prakash and Jwalit Hasmukhlal Sheth. "Intracranial Malignant Nerve Sheath Tumor in the Middle Cranial Fossa: A Rare Case Report with Review of Literature". *Asian Journal of Neurosurgery* 14.3 (2019) 922-926.
- Lee BS., et al. "A Long-Term Survival Case of a Primary Malignant Intracerebral Nerve Sheath Tumor". *Journal of Korean Neurosurgical Society* 54 (2013): 261-264.
- Kumar R., et al. "Malignant intracerebral nerve sheath tumour (MINST) simulating malignant glioma". *Pan Arab Journal of Neurosurgery* 14.1 (2010): 19-23.

20. Barnard ZR, *et al.* "Sporadic primary malignant intracerebral nerve sheath tumors: case report and literature review". *Journal of Neuro-Oncology* 104 (2011): 605-610.
21. Tanaka M., *et al.* "Malignant intracerebral nerve sheath tumor with intratumoral calcification". *Journal of Neurosurgery* 92.2 (2000): 338-341.
22. Beauchesne P, *et al.* "Malignant Nerve Sheath Tumor of the Right Cerebral Peduncle: Case Report". *Neurosurgery* 54.2 (2004): 500-504.
23. Le Fèvre C., *et al.* "[Malignant intracerebral nerve sheath tumours: Two case reports and complete review of the literature cases]". *Cancer Radiotherapie* 20.2 (2016): 119-132.
24. Nabavizadeh SA and Vossough A. "Malignant pediatric intracerebral nerve sheath tumor in neurofibromatosis type 1". *Child's Nervous System* 25.517 (2009).
25. Oztanir N., *et al.* "Malignant intracerebral giant nerve sheath tumor in a 14-month-old girl with neurofibromatosis type 1: A case report". *Child's Nervous System* 25 (2009) 253-256.
26. Stefanko SZ., *et al.* "Intracerebral malignant schwannoma". *Acta Neuropathologica* 71 (1986): 321-325.
27. Prakash B., *et al.* "Schwannoma of the brain stem". *Journal of Neurosurgery* 53 (1980): 121-123.

#### Assets from publication with us

- Prompt Acknowledgement after receiving the article
- Thorough Double blinded peer review
- Rapid Publication
- Issue of Publication Certificate
- High visibility of your Published work

**Website:** [www.actascientific.com/](http://www.actascientific.com/)

**Submit Article:** [www.actascientific.com/submission.php](http://www.actascientific.com/submission.php)

**Email us:** [editor@actascientific.com](mailto:editor@actascientific.com)

**Contact us:** +91 9182824667