

Breast Cancer Metastas in Myofibrosarcoma

Vincenza Roberto*

Oncology Clinic of Kalmar Hospital, Sweden

*Corresponding Author: Vincenza Roberto, Oncology Clinic of Kalmar Hospital, Sweden.

Received: April 08, 2019; Published: April 24, 2019

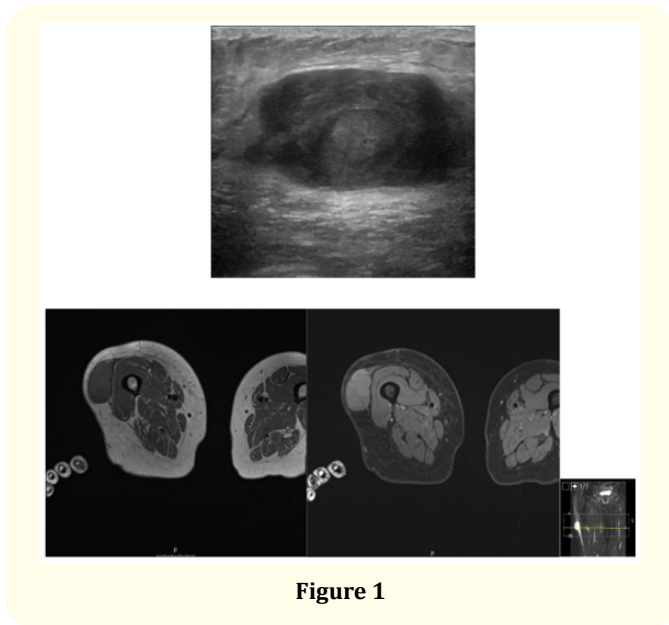


Figure 1

An 80-year-old woman was seen in the Oncology Clinic for physical examinations during her second line endocrine treatment with fulvestrant because of lung and skeletal metastatic breast cancer. During the physical examination I noticed a mass in the lateral side of the right thighs which measured 7x7 cm, with round edges, hard and fixed to the underlying tissue. Patient reported that this mass come 3-4 mounts earlier and has now grown.

She was diagnosed with breast cancer 18 year earlier when she underwent right-side mastectomy and axillary surgery because of pT2N1 invasive ductal cancer estrogen receptor-positive, thereafter adjuvant radiation therapy and Tamoxifen for 2 years. Year 2016 diagnosis of left side metastatic breast cancer where biopsy showed estrogen receptor-positive Her2-negative invasive ductal cancer and patient started first line treatment with aromatase-inhibitor and underwent a palliative partial mastectomy. When was 50, patient has had a surgery for a superficial spreading malignant melanoma on the right leg, Breslow 1,3 mm, Clark III. Genetic analysis is ongoing.

Ultrasound right thigh showed a big mass with low echogenicity but solid character, which measured about 8 x 5 x 2.5 cm in diameter. The tumour had some multilobular contours and lied with a broad base on the muscle fascia and there was plenty of blood vessels within it. The tumour was only about half a cm below the skin surface. Finds whose appearance raised a great suspicion of sarcoma. MR right thigh with and without intravenous contrast showed a large and somewhat multilobular tumour on the lateral side in the middle part of the thigh. The mass was quite well contoured, it was in the subcutaneous fat with a broad base on the iliotibial tract and the muscle fascia along the vastus lateralis but no signs of ingrowth into the muscle itself. It measured up to about 5.5 x 3 cm in cross-section and about 7 cm cranially caudal. The tumour had an elevated signal on T2-weighted sequences and a lower signal on T1, similar to muscle tissue. After intravenous contrast enhancement, it demonstrated vigorous charging, there were also a few smaller areas within the tumour without contrast charging indicative of necrosis.

The mass has been first biopsied, and the immunohistochemistry analysis revealed two tumour components, a minimal part of epithelial cells positive for CKAE1/AE3, CKCAM, EMA, GATA3 and about 30% of estrogen receptor expression which, despite of negative for mammoglobine, indicates like metastasis of patient breast cancer. The second tumour component was unclear but CD34, CD99 and p16 was positive and almost cytocheratins negative. The mass was operated, and the immunohistochemistry analysis revealed an high grade 8x5, 5x4 cm myxofibrosarcoma, grade 3 French Grading System, 16/10 HPF mitosis, 25% ki67, SMA, Caldesmon, S100, SOX10, STAT6 negative, in some pieces notes the growth of patient's previous breast cancer.

The sarcoma was radical operated, and patient continues treatment for metastatic breast cancer.

Volume 3 Issue 5 May 2019

© All rights are reserved by Vincenza Roberto.